



UNIVERSITATEA DE STAT DE MEDICINĂ ȘI FARMACIE  
„NICOLAE TESTEMIȚANU” DIN REPUBLICA MOLDOVA

Catedra Oftalmologie

# Anatomical and clinical features of the Eye

*Associate Professor*  
*ALA PADUCA*



# Objectives:

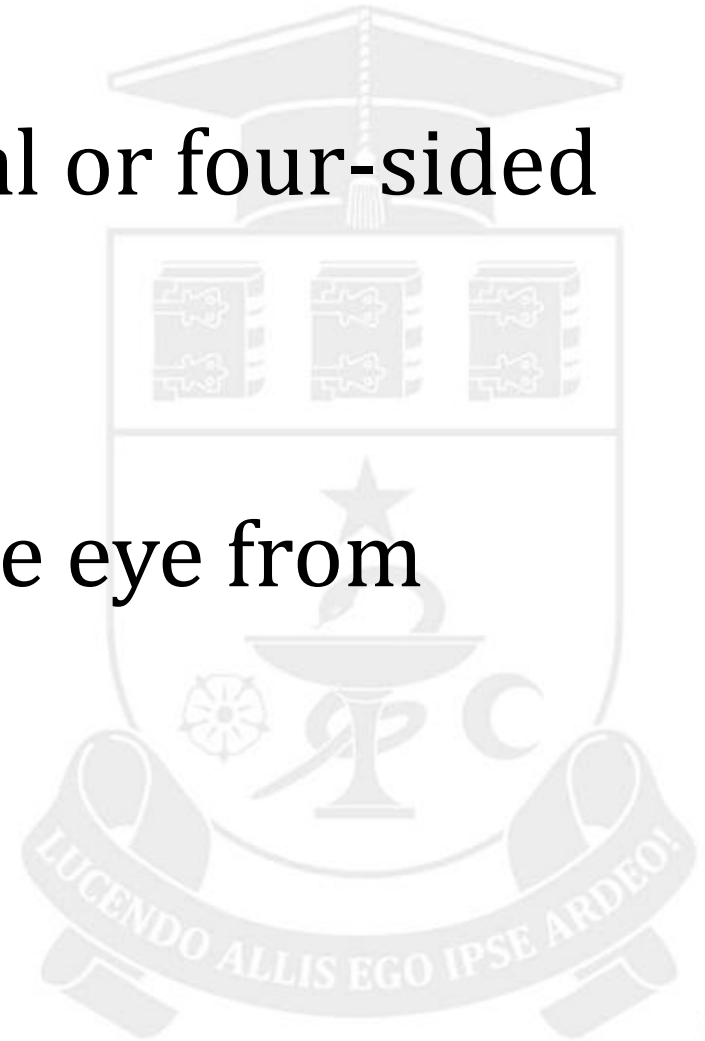
- To learn the anatomy and clinical features of the orbit, eye and eye adnexa.





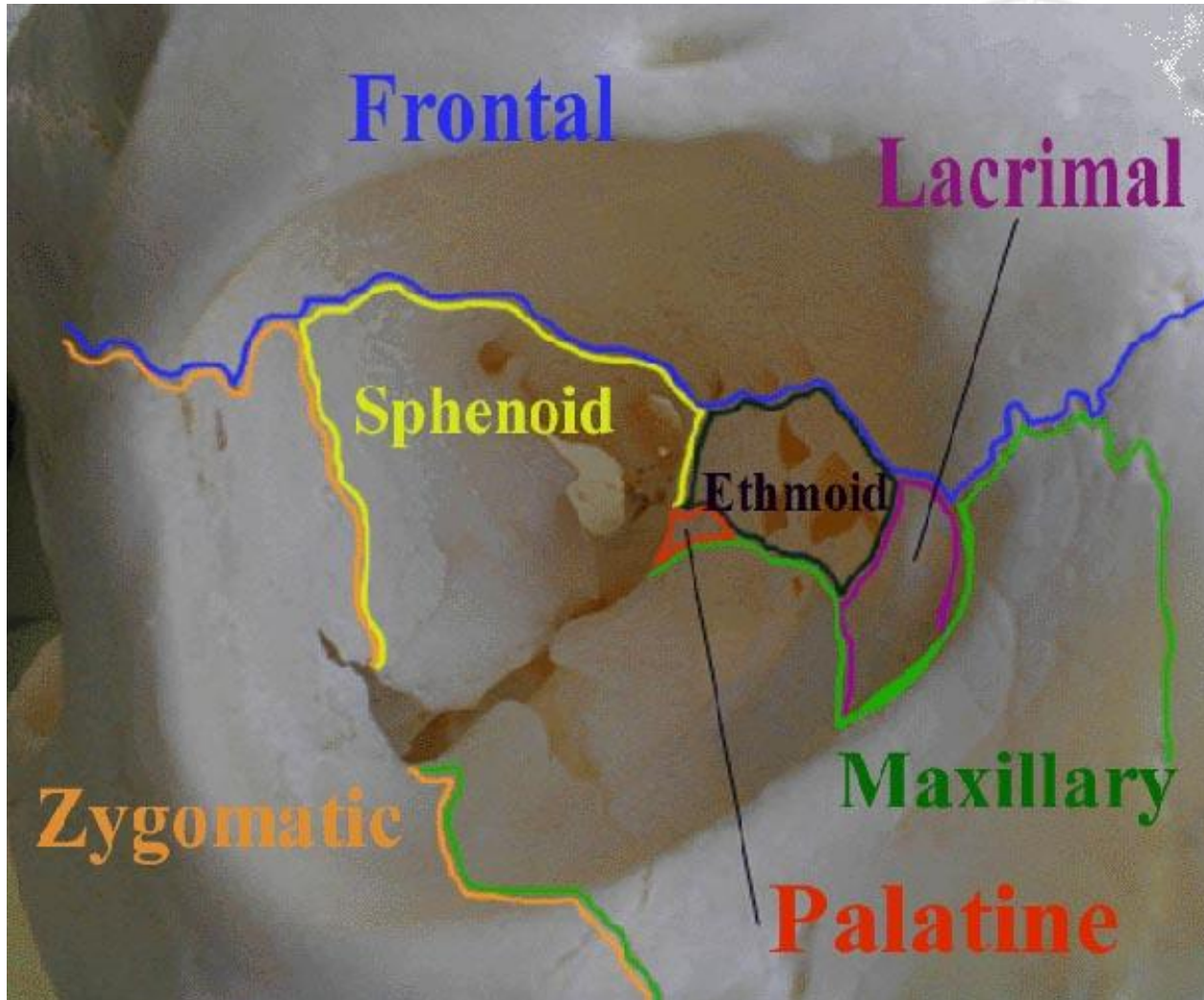
# The orbit

- The orbits are conical or four-sided pyramidal cavities.
- Function - Protect the eye from mechanical injury.





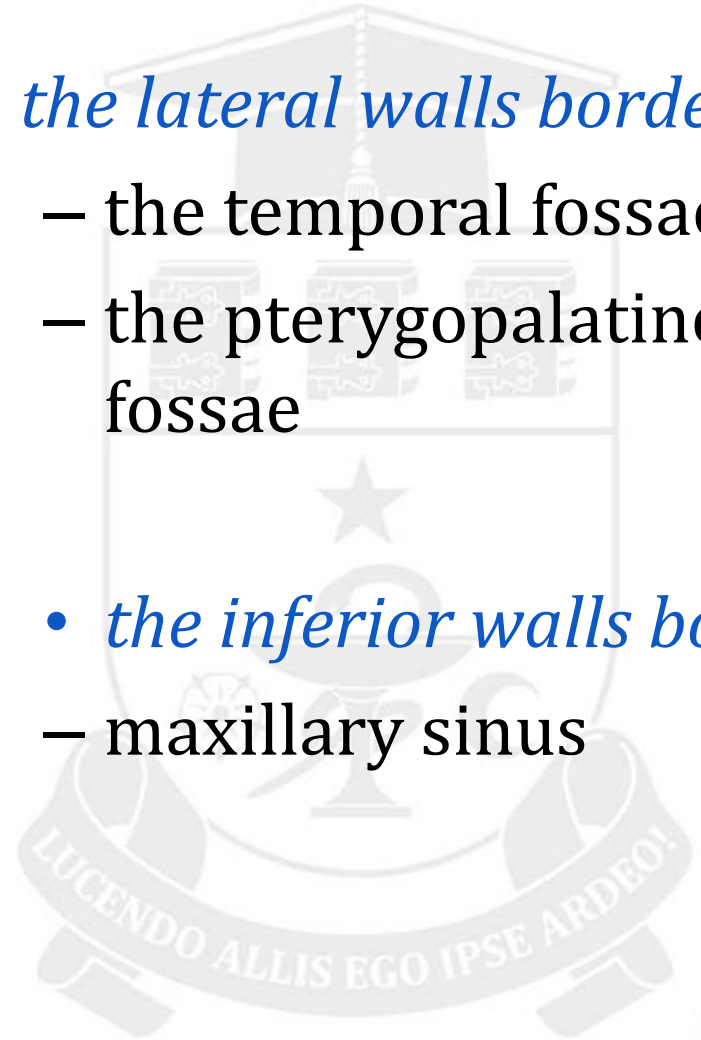
# Seven bones make up the bony orbit:






# The orbital walls border:

- *the medial walls border:*
  - nazal cavity
  - the ethmoidal cells
  - the sphenoid sinus
- *the superior walls border:*
  - anterior cranial fossae
  - frontal sinus
- *the lateral walls border:*
  - the temporal fossae
  - the pterygopalatine fossae
- *the inferior walls border:*
  - maxillary sinus





- 1. Injury of which wall is consider to be most dangerous?



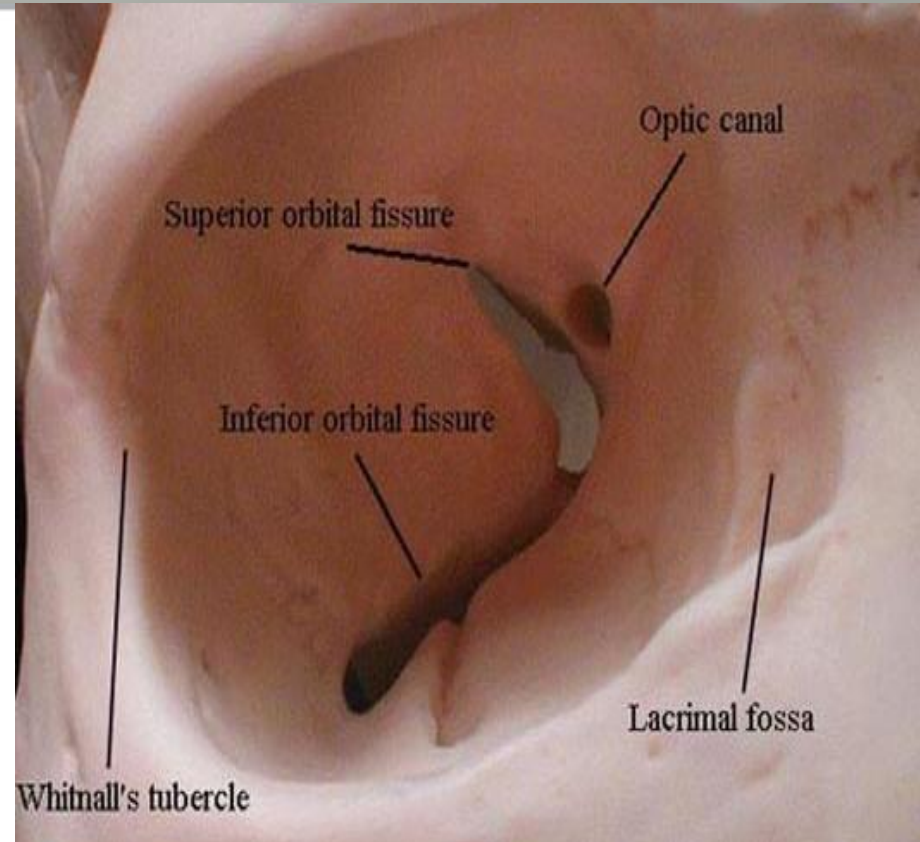


- *The superior orbital fissure (between the greater and the lesser wings of the sphenoid bone) and transmits:*

- oculomotor nerve III
- abducens nerve VI
- trochlear nerve IV
- Lacrimal nerve
- Frontal nerve
- I - branch of cranial nerve V  
trigeminal ophthalmic
- superior ophthalmic vein

- *The inferior fissure (between the lateral wall and the floor) and transmits:*

- inferior ophthalmic vein
- the second branch of V nerve  
(maxillary)



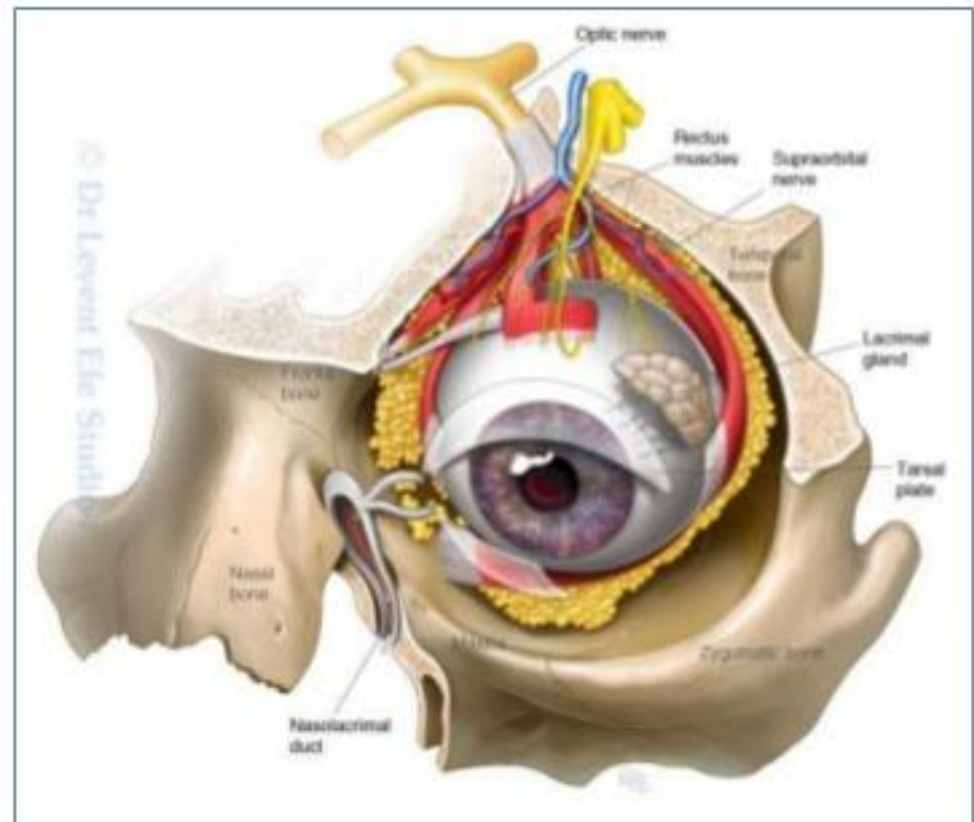
- *The optic foramen conducts the:*

- optic nerve
- ophthalmic artery



- The eye balls,
- extra ocular muscles,
- nerves,
- vessels,
- fat,
- and most of the lacrimal apparatus
- with the optic nerve as its stem
- Volume: 30 cc

## Orbital contents

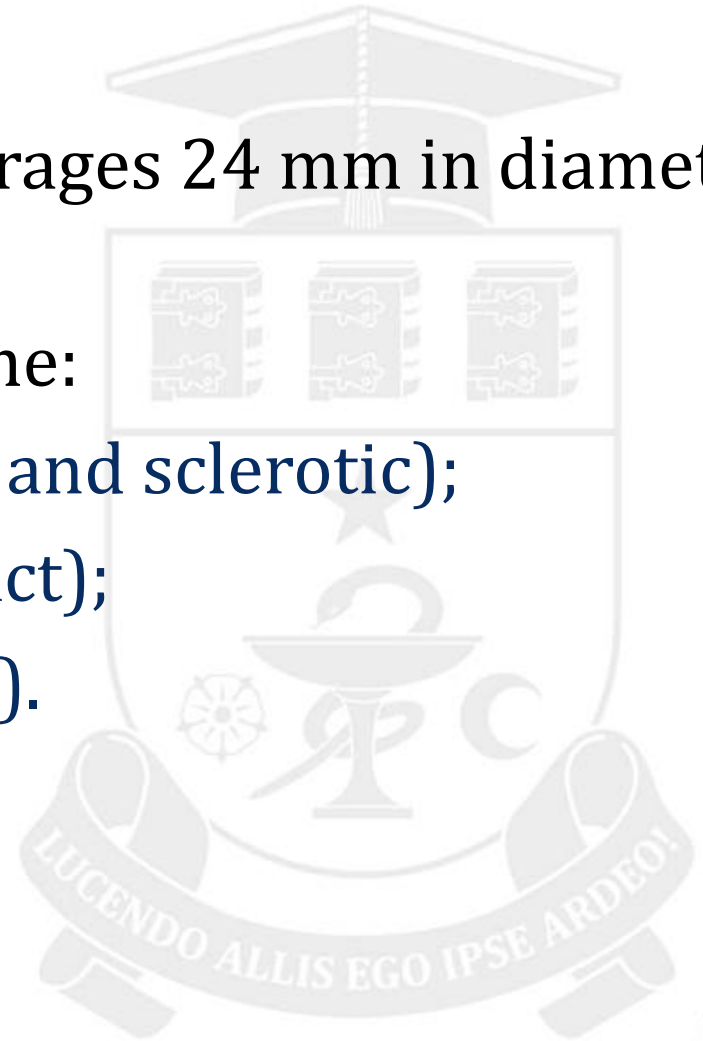






# THE EYE

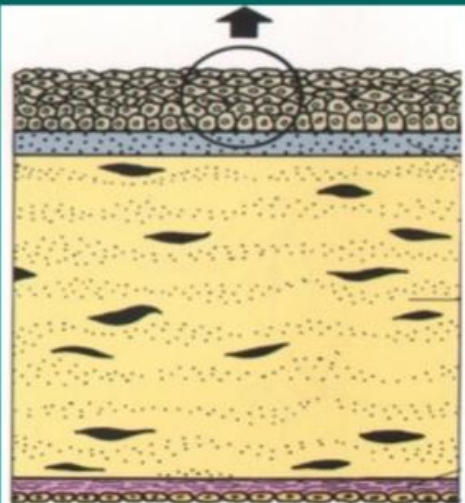
- The adult human eye averages 24 mm in diameter (at birth it is 16 mm)
- The globe has 3 membrane:
  - anterior (cornea and sclerotic);
  - medial (uveal tract);
  - posterior (retina).





# CORNEA

- Occupies the center of the anterior pole of the globe it measures about:
  - 11.5 to 12.6 mm *horizontally*
  - 10.5 to 11.7 mm *vertically*
- Characteristics: spherical, transparent;
- The cornea has 5 layers:



- Epithelium
- Bowman membrane
- Stroma
- Descemet membrane (posterior limiting layer of cornea)
- Endothelium



- ***The functions of the cornea:***

- refractive (+44D)- the main refractive element of the eye
- protection the internal ocular structures

5<sup>th</sup> CN (trigeminal nerve)



ophthalmic division

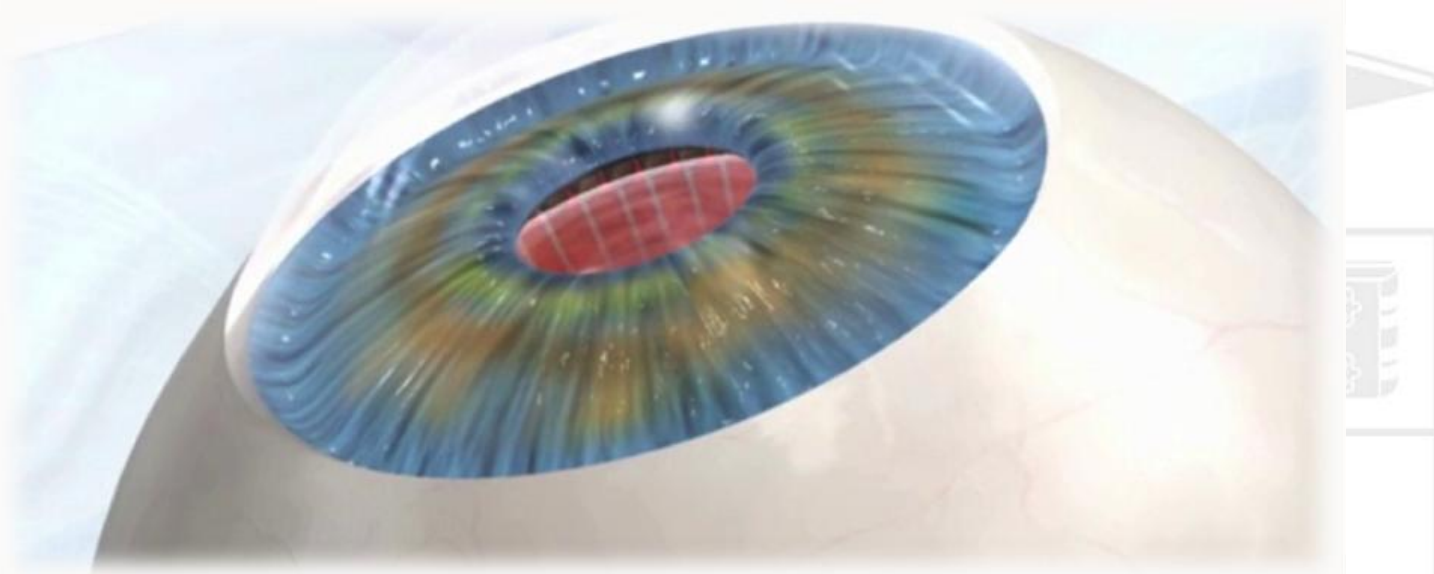


nasociliary nerves (70–80 long ciliary nerves and short ciliary nerves).

- ***Innervation:***



# Nutrition of the cornea



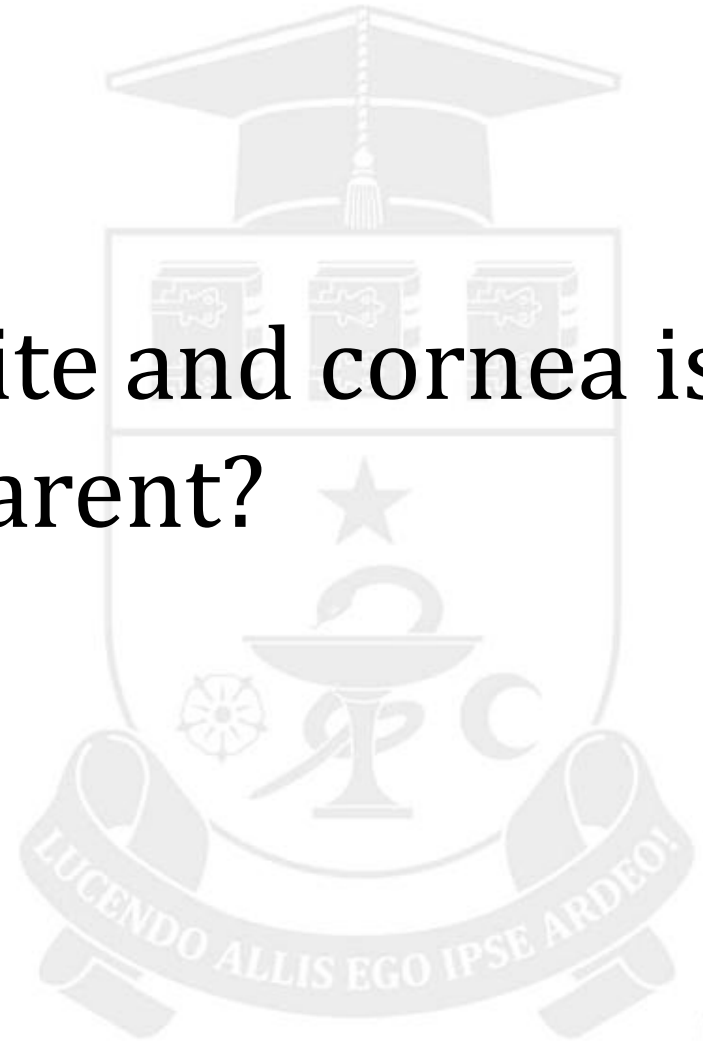
**Cornea is the only part of your body that has no blood supply, it gets oxygen directly from air**

- Tears
- Aqueous humor
- Perilimbal vessels



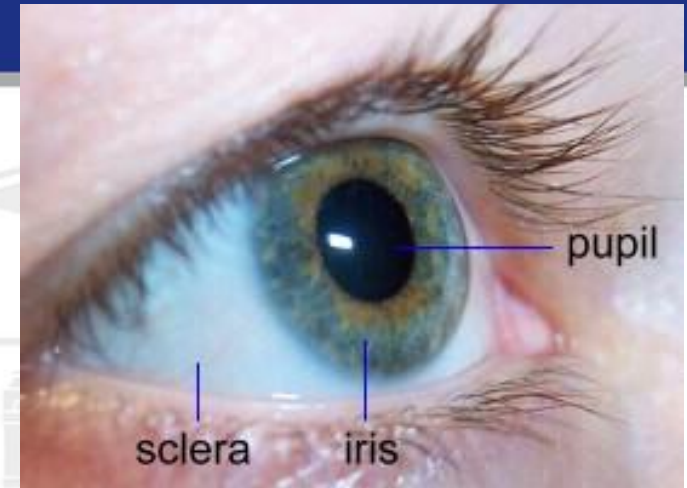

Why sclera is white and cornea is transparent?





# SCLERA - “white of the eye”

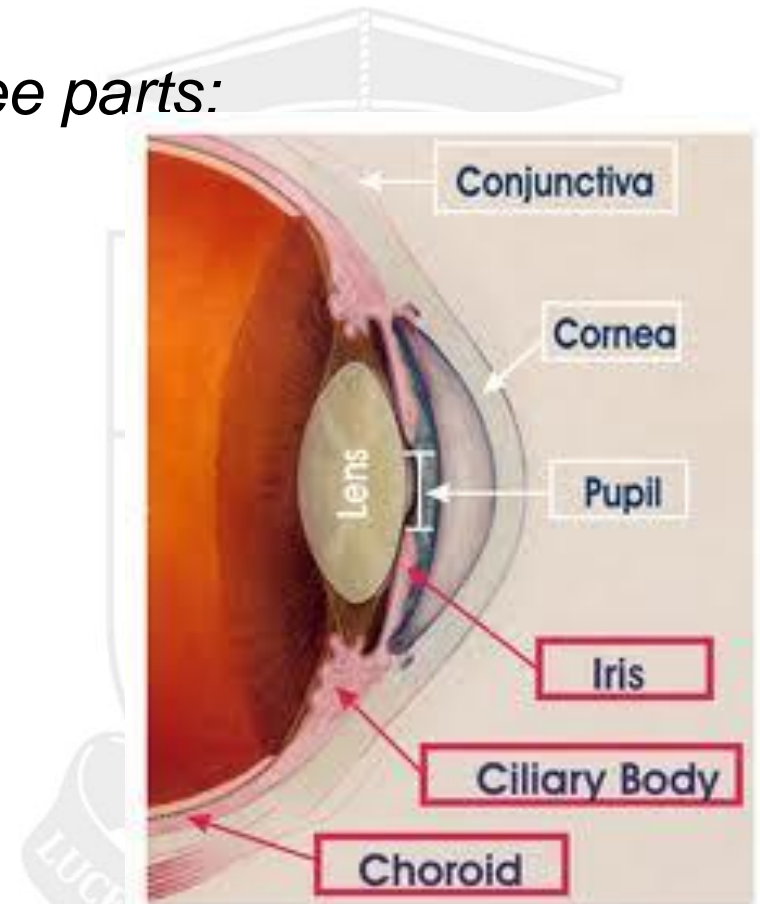


- fibrous protective membrane (highly compacted flat bands of collagen bundles which interweave in all directions)
- Covered anteriorly by episclera then by the *conjunctiva*
- Thinnest **behind the rectus muscle insertions**
- **The limbus** - the transition zone between the cornea and the sclera



# UVEAL TRACTS


- *Uveal tracts it consists of three parts:*
  - iris
  - ciliary body
  - Choroid



[http://www.doctor-hill.com/patients/uveitis\\_arizona.htm](http://www.doctor-hill.com/patients/uveitis_arizona.htm)



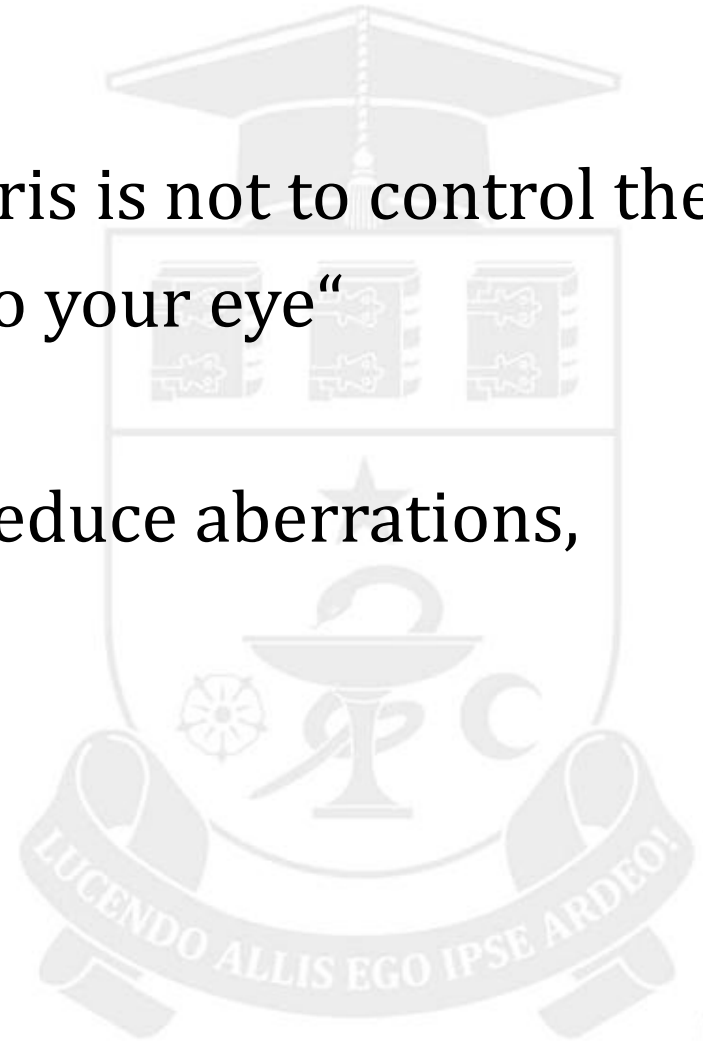
- *The **iris** - it is made up of:*
  - blood vessels
  - connective tissue
  - 2 muscles:
    - *dilatator (is innervated by the sympatic system)*
    - *sphincter muscles (is innervated by the parasympatic system)*







- The main *function* of the iris is not to control the intensity of light coming into your eye“
- Main functions of iris“ o reduce aberrations, sharpen image

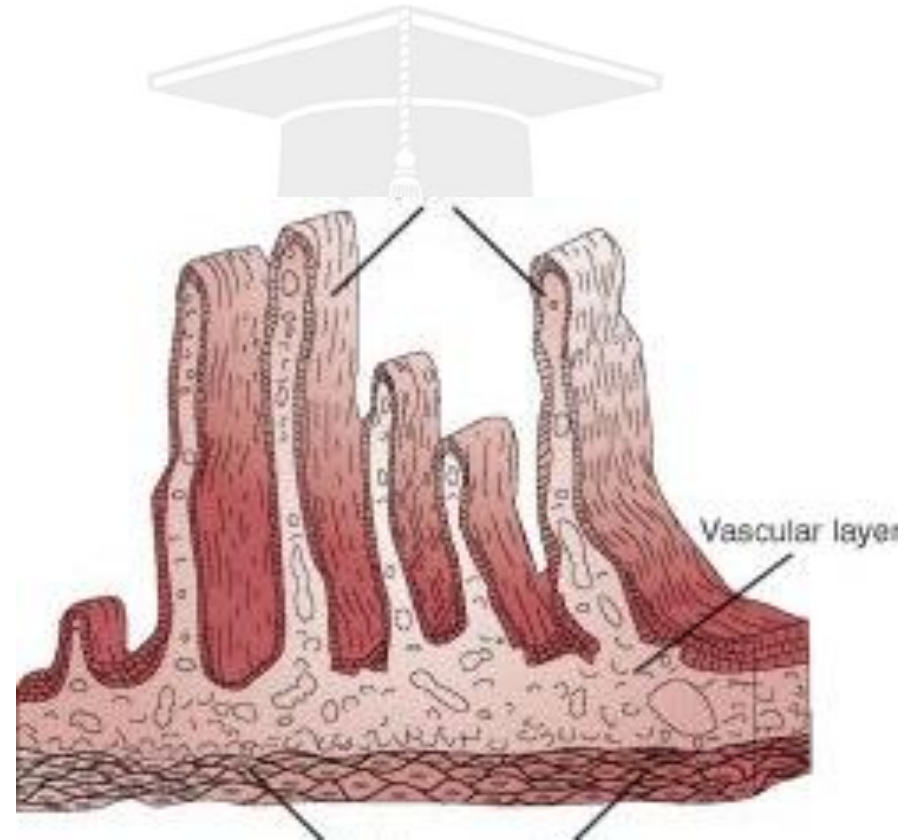




# CILIARY BODY

*This is subdivided into three parts:*

- the ciliary muscle
  - the ciliary processes
  - the pars plana
- *Blood supplies:*
- Long posterior ciliary artery
  - Anterior ciliary artery






# CILIARY BODY

## *Functions:*

- aqueous humor formations,
- lens accommodation.

*Vascularisation* for the ciliary body comes from blood vessels which also supply the iris.






# CHOROID

- The posterior portion of the uveal tract is generally divided into four layers:
- Haller's layer - outermost layer of the choroid consisting of larger diameter blood vessels;
- Sattler's layer - layer of medium diameter blood vessels;
- Choriocapillaris - layer of capillaries; and
- Bruch's membrane (synonyms: Lamina basalis, Lamina vitra) - innermost layer of the choroid



## *CHOROID Function:*

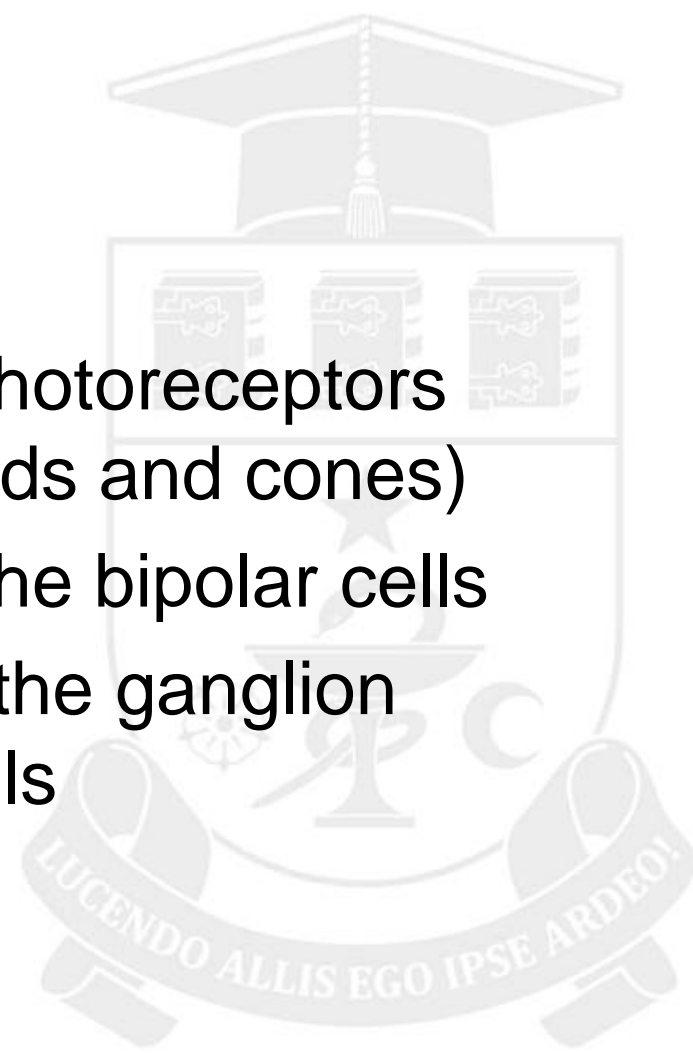
- allimentation (provides oxygen and nourishment to the retina. )





# RETINA

- *The retina it is divided into ten separate layers with 3 neurones:*
  - I photoreceptors (rods and cones)
  - II the bipolar cells
  - III the ganglion cells

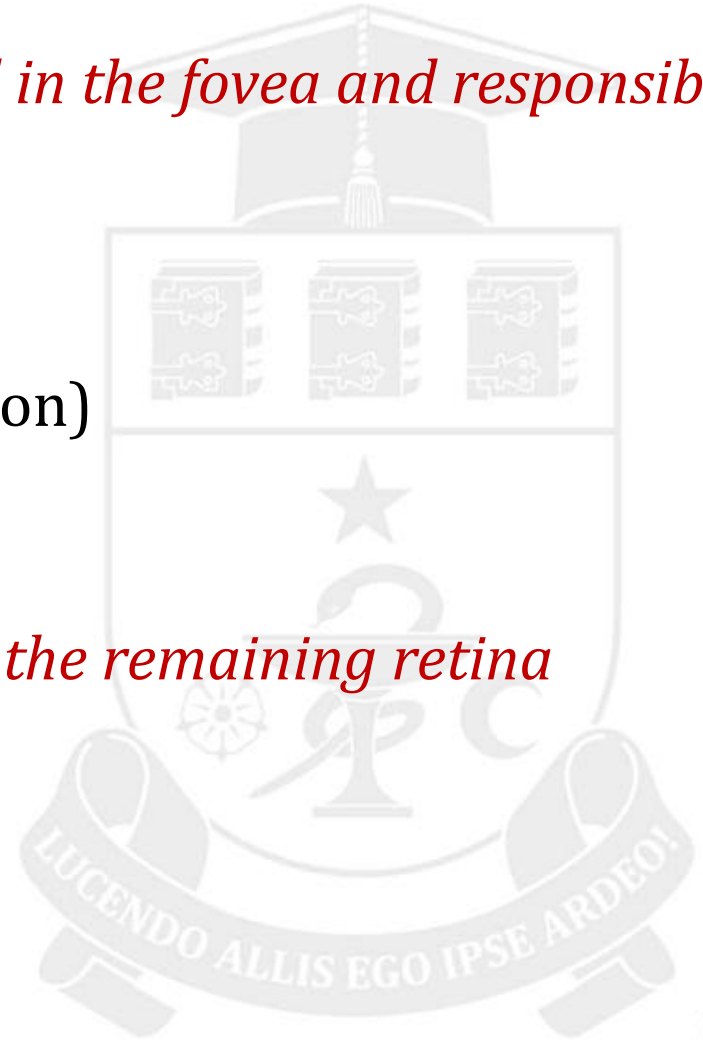




# Photoreceptors (rods and cones) "

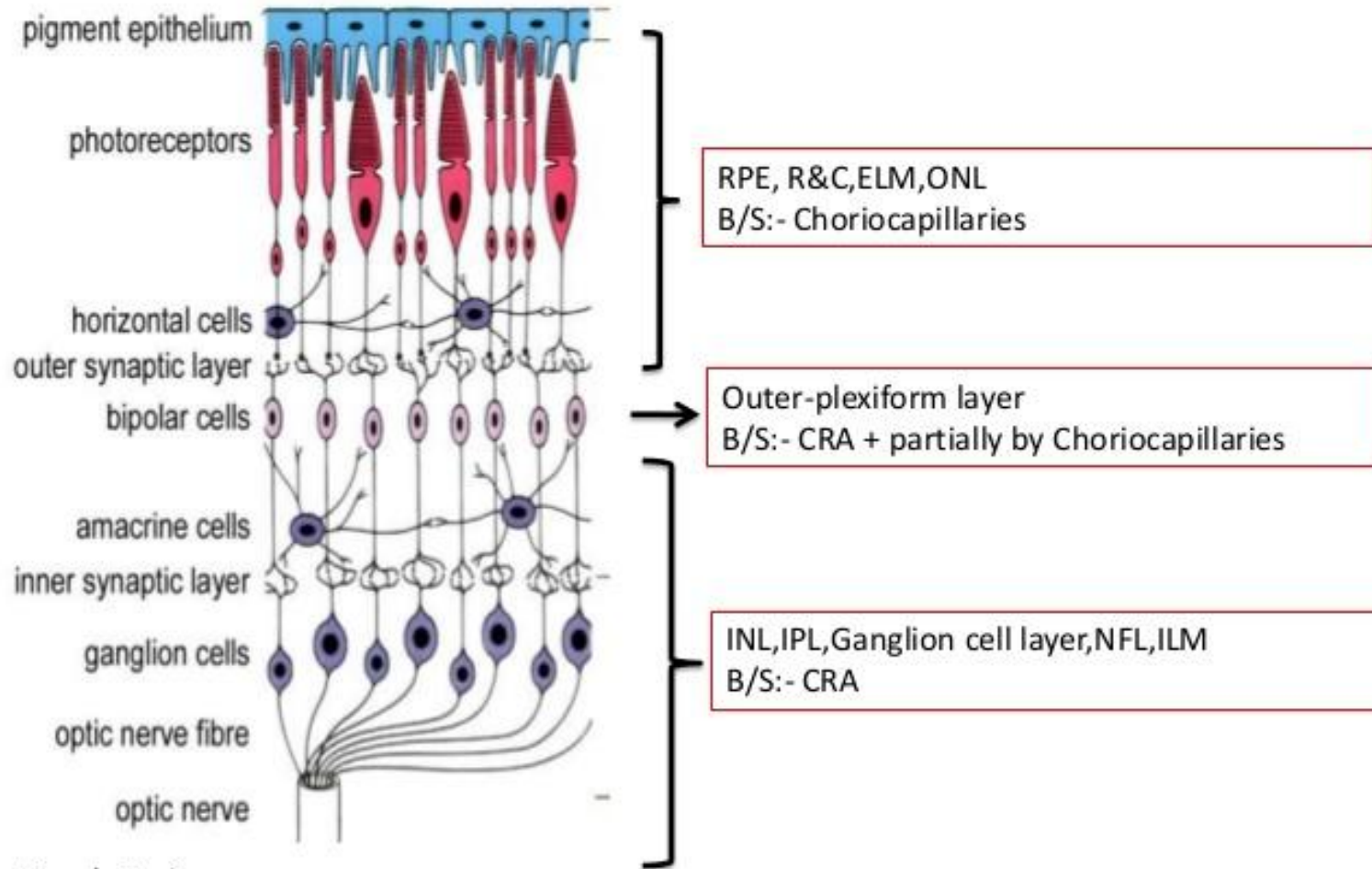
## convert light into electrical signal

- *Cones ( 7 mln) are concentrated in the fovea and responsible for:*
  - Daylight vision
  - Color vision
  - Central vision (fine detailed vision)
- *Rodes (130mln) are situated in the remaining retina*
  - Low light vision
  - Peripheral vision
  - Black – white vision





# Blood supply



## Macula Region

B/S:- Superior & Inferior temporal branches

**\*\*In 20% population Cilioretinal Artery supplies macula.** (in case of CRA occlusion it helps to retain vision)

**\*\*Retinal art. are END ARTERIES.**





# The Visual Pathway

The visual pathway from the retina has been divided into 6 parts:

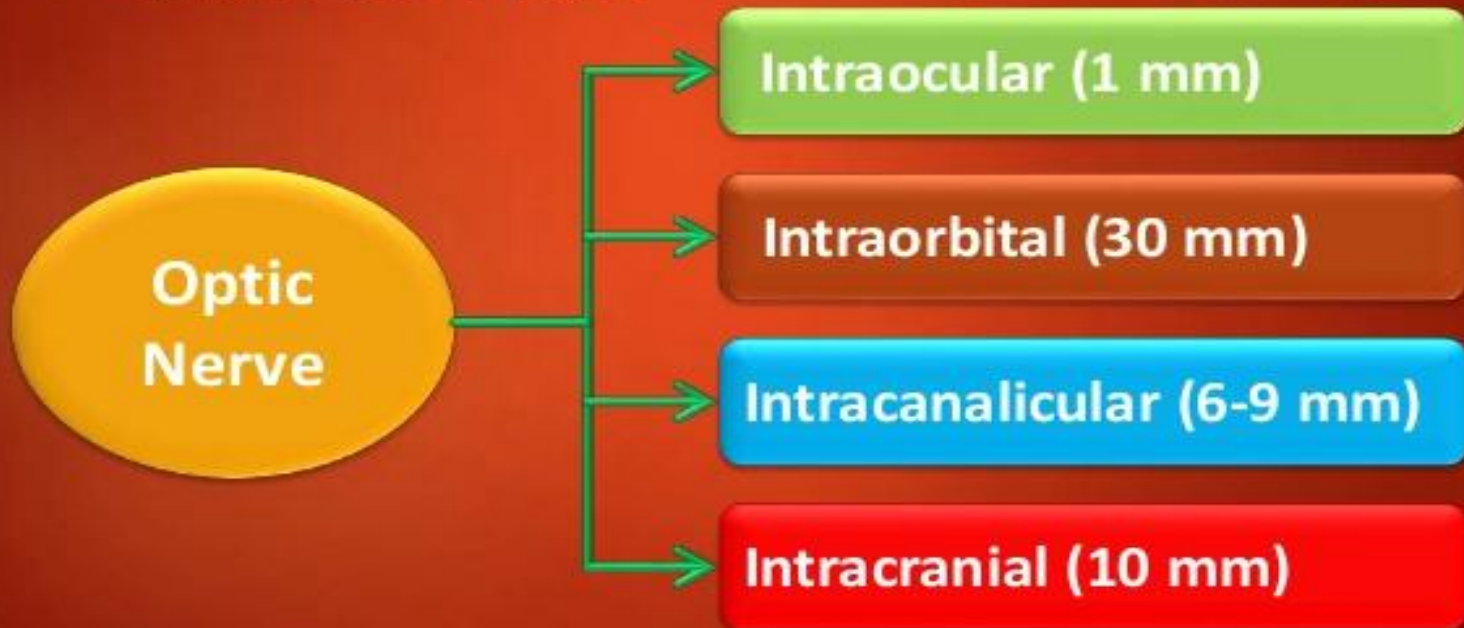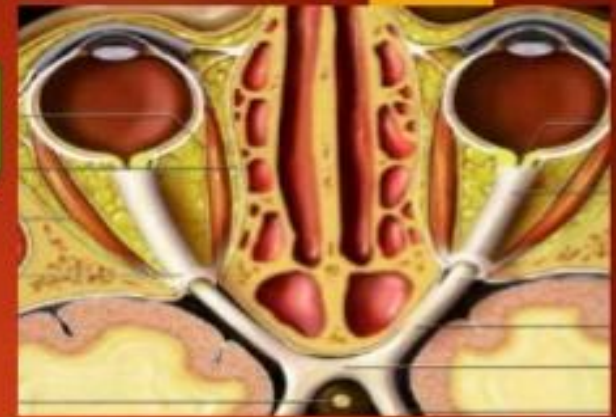- Optic nerve
- Optic chiasma
- Optic tract
- Lateral geniculate body
- Optic radiations
- Visual cortex





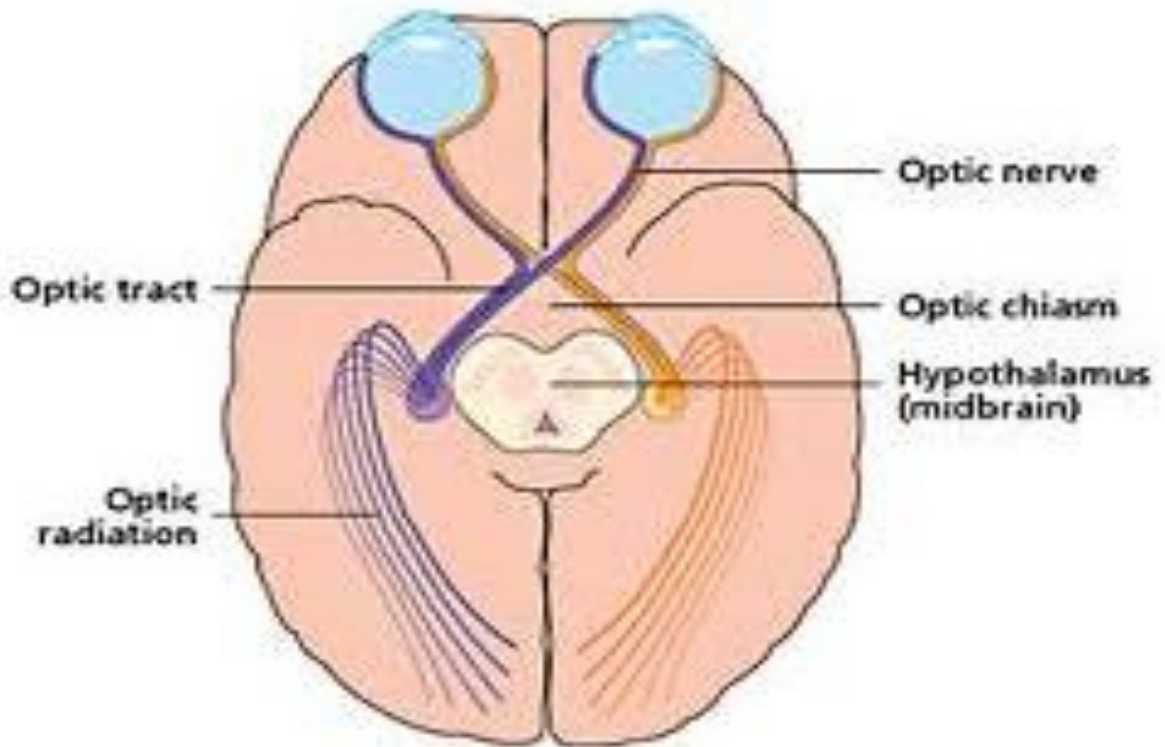
## Parts of Optic Nerve

- ❖ About 47-50 mm in length
- ❖ Divided into 4 parts:






- The medial fibers (nazal) cross in the chiasm.
- The visual center is situated in the occipital lobe.





The membranes of the eye **includ** this structures:

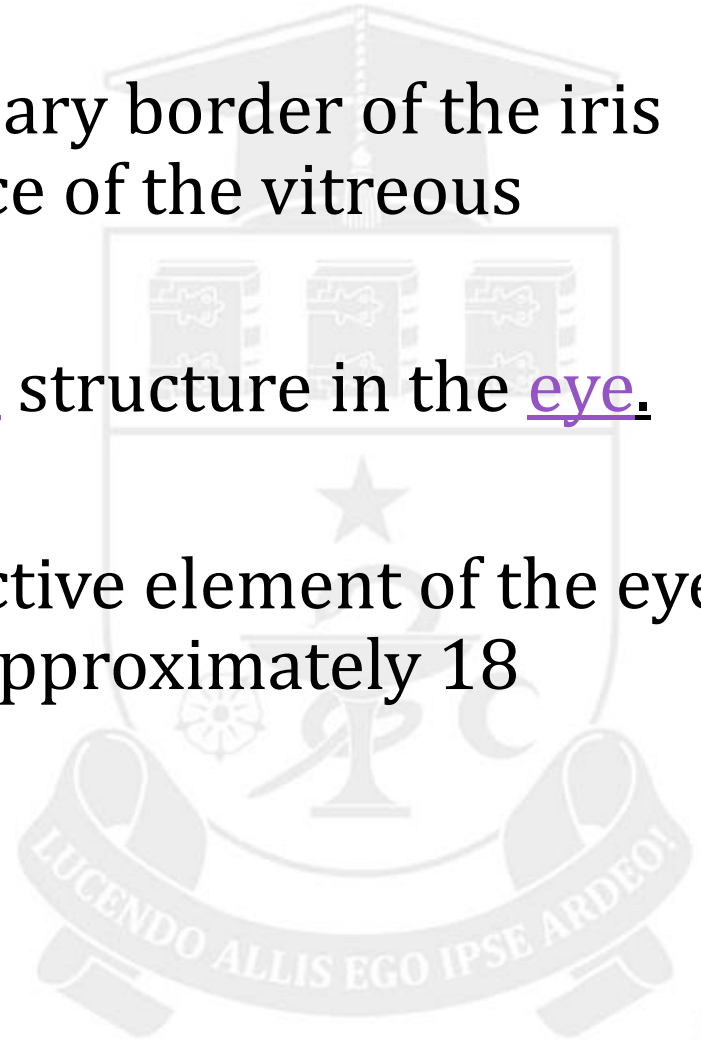
- Aqueus humor
- Lens
- The vitreous

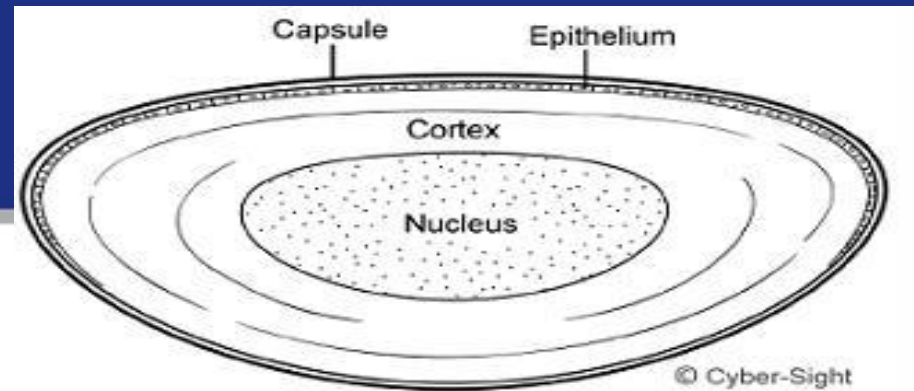




# The LENS

- Situated behind the pupillary border of the iris and on the anterior surface of the vitreous
- Is a transparent, biconvex structure in the eye.
- Is the second major refractive element of the eye (the refractive power is approximately 18 dioptries);
- Grows throughout life.





- Is supported by zonular fibres – *zonule of Zinn* – running between the ciliary body and the lens capsule.
  - It has two parts: central – nucleus and the peripheral or cortex.
  - The lens is avascular and not innervated.
- Its nutrition is maintained by the aqueous humor.

[http://telemedicine.orbis.org/bins/volume\\_page](http://telemedicine.orbis.org/bins/volume_page).

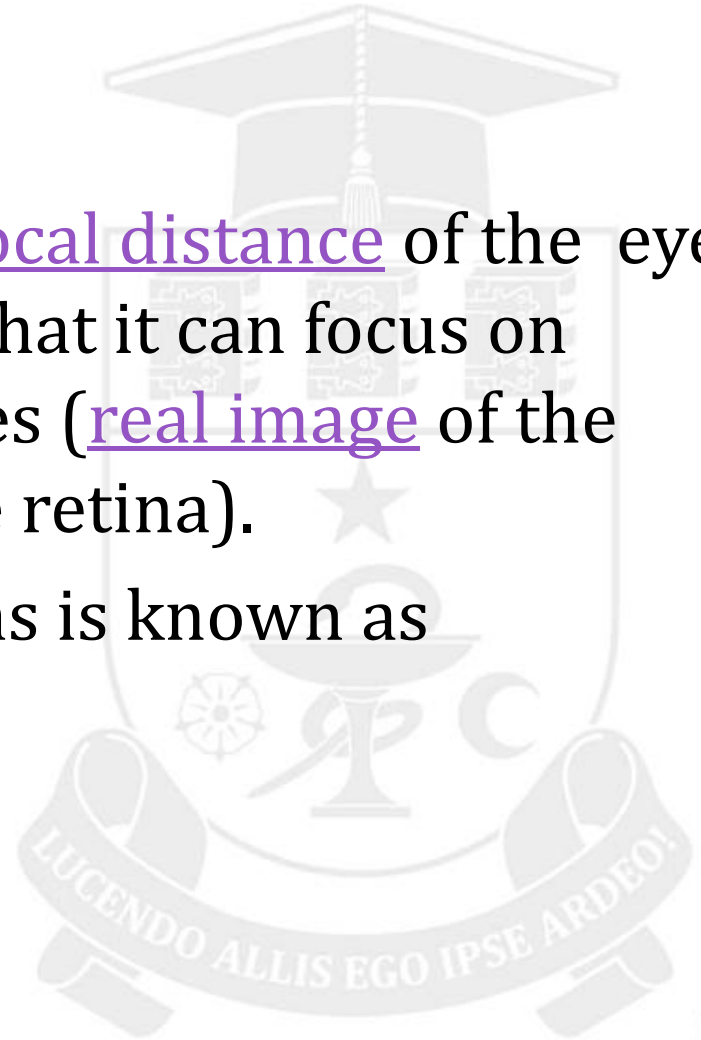
- Module 3: A Nurses Guide to Basic Anatomy and Physiology of the Eye - The Eye



# The LENS

- **Function** - to change the focal distance of the eye by changing shape of eye so that it can focus on objects at various distances (real image of the object to be formed on the retina).

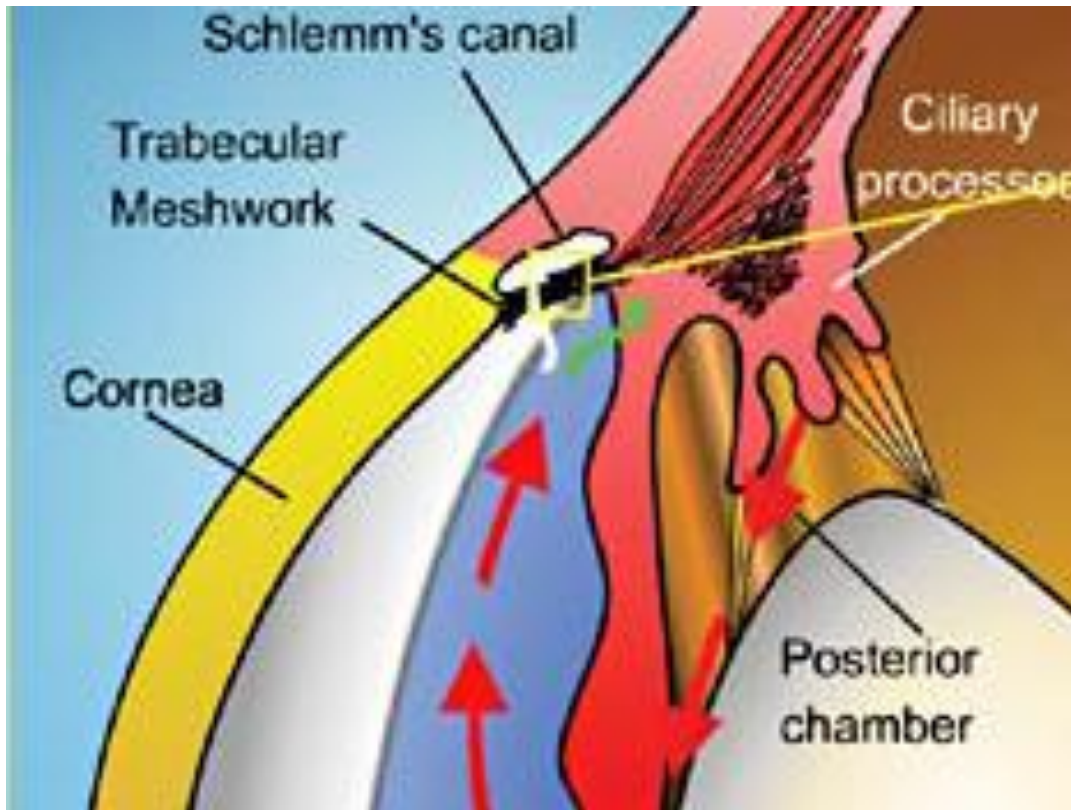
This adjustment of the lens is known as accommodation





# Aqueous Humor

The ciliary body secretes the humor into the posterior chamber



Through the pupil into the anterior chamber

trabecular meshwork spongy tissue

Schlemm's canal


Into the bloodstream.





# Vitreous Humour

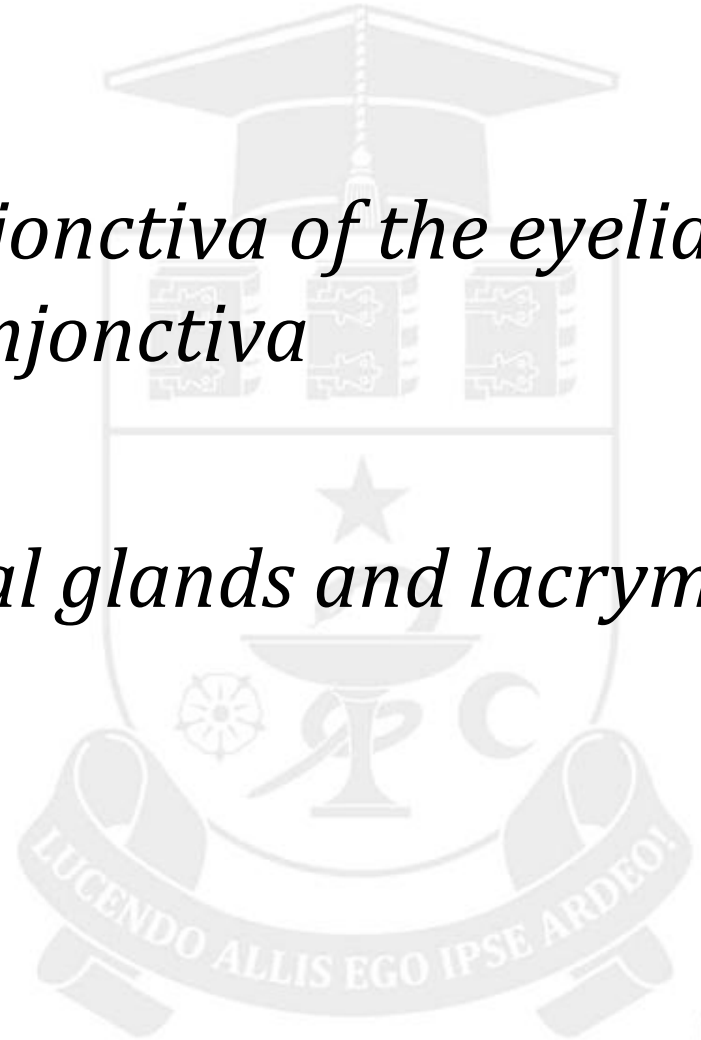
- A jelly-like transparent fluid fills the inner chamber of the eye and it is contained in a thin membranous sac called the hyaloid membrane.
- 98% of water





# Adnexae of the eye:

- **the conjunctiva:** *conjunctiva of the eyelids (tarsal) and bulbar conjunctiva*
- **the eyelids**
- **the tear film:** *lacrymal glands and lacrymal drainage system*





# The conjunctiva

- is a mucous membrane that lines the lids and also covers the surface of the eyeball.
- It permits a certain degree of rotation of the eyeball in the orbit.

The conjunctiva is divided in 2 portions:

1. that lines the lids - the palpebral portion
2. the part that covers the white of the eyeball - the bulbar conjunctiva.

The other parts of the conjunctiva include two loose recesses, known as the upper and lower fornices.



# The conjunctiva

## □ Blood Supply

- anterior ciliary artery
- palpebral arteries

## □ Nerve Supply

- first division of the trigeminal nerve





# The eyelids

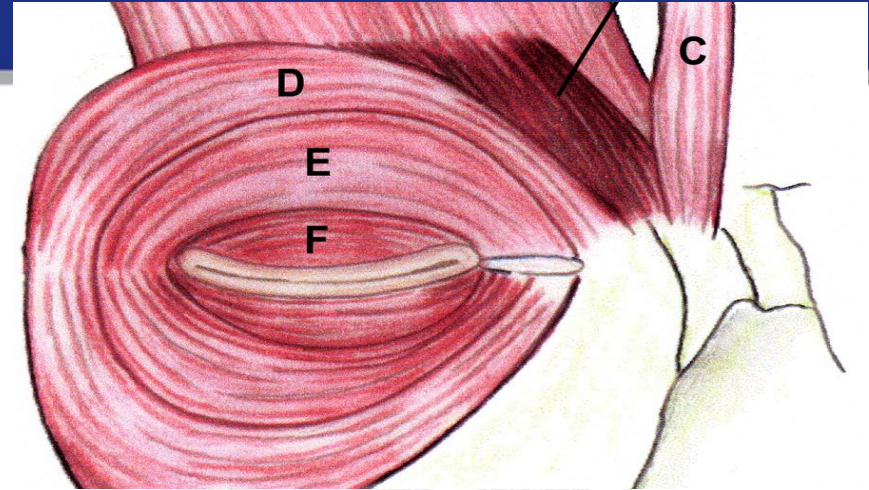
**Layers:** skin, subcutaneous tissue, orbicularis oculi, orbital septum & tarsal plates, and palpebral conjunctiva.

**Arterial supply:** anastomosis from two sources: facial system and orbital system (branches of the ophthalmic artery).

**Nerve supply:** motor- facial nerve; sympathetic (Muller muscle); sensory; upper eyelid- supraorbital, infraorbital, supratrochlear, lacrimal  
Lower eyelid = infraorbital and lacrimal



# The Orbicularis oculi



(A) Frontalis, (B) corrugator superciliaris, (C) procerus, (D) orbital orbicularis, (E) preseptal orbicularis, (F) pretarsal orbicularis (*Orbicularis palpebrarum*) arises from the nasal part of the frontal bone,

The muscle may be arbitrarily divided into the orbital (fig. D) and palpebral parts (fig. F).

**Function:** The palpebral portion is used in blinking and voluntary winking, while the orbital portion is used in forced closure.

**Innervation:** Facial nerve

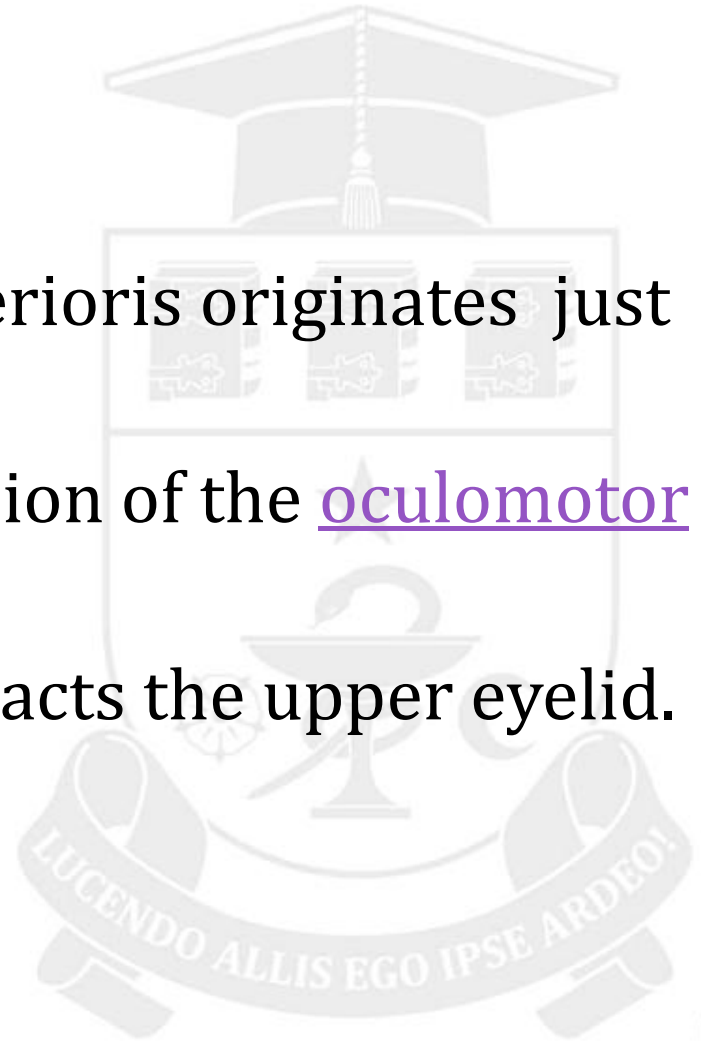


# The levator palpebrae superioris

The levator palpebrae superioris originates just above the optic foramen

*Innervation:* superior division of the oculomotor nerve (Cranial Nerve III)

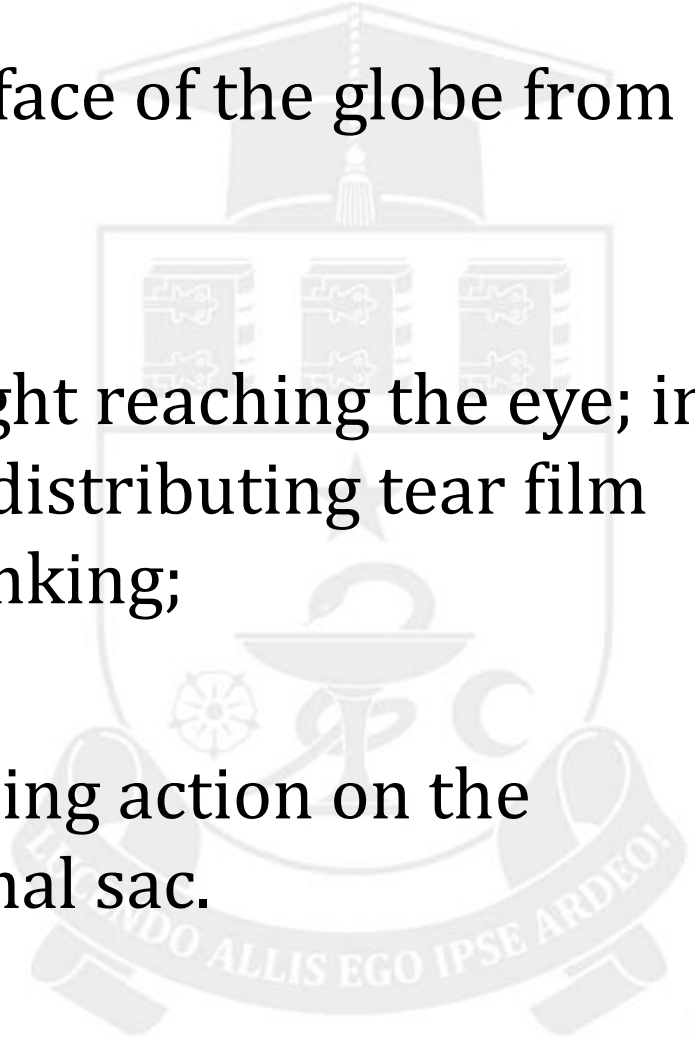
*Function:* elevates and retracts the upper eyelid.





# FUNCTION OF THE EYELIDS

- to protect the anterior surface of the globe from local injury.
- they aid in regulation of light reaching the eye; in tear film maintenance, by distributing tear film over the cornea during blinking;
- in tear flow, by their pumping action on the conjunctival sac and lacrimal sac.

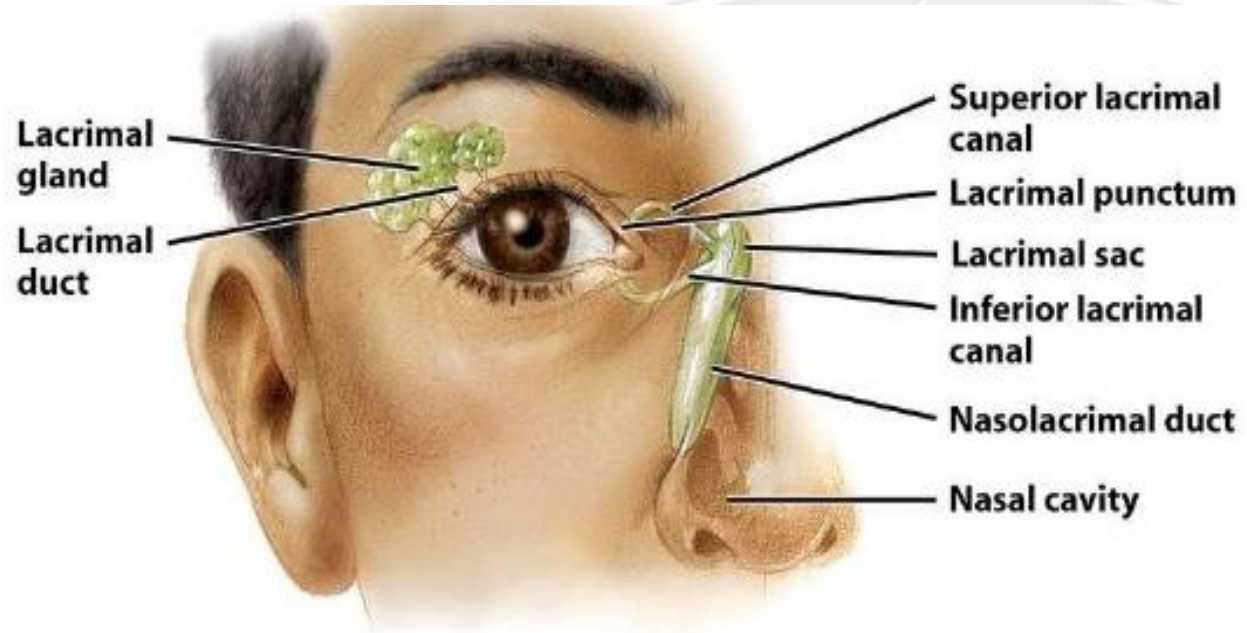






# THE LACRIMAL APPARATUS

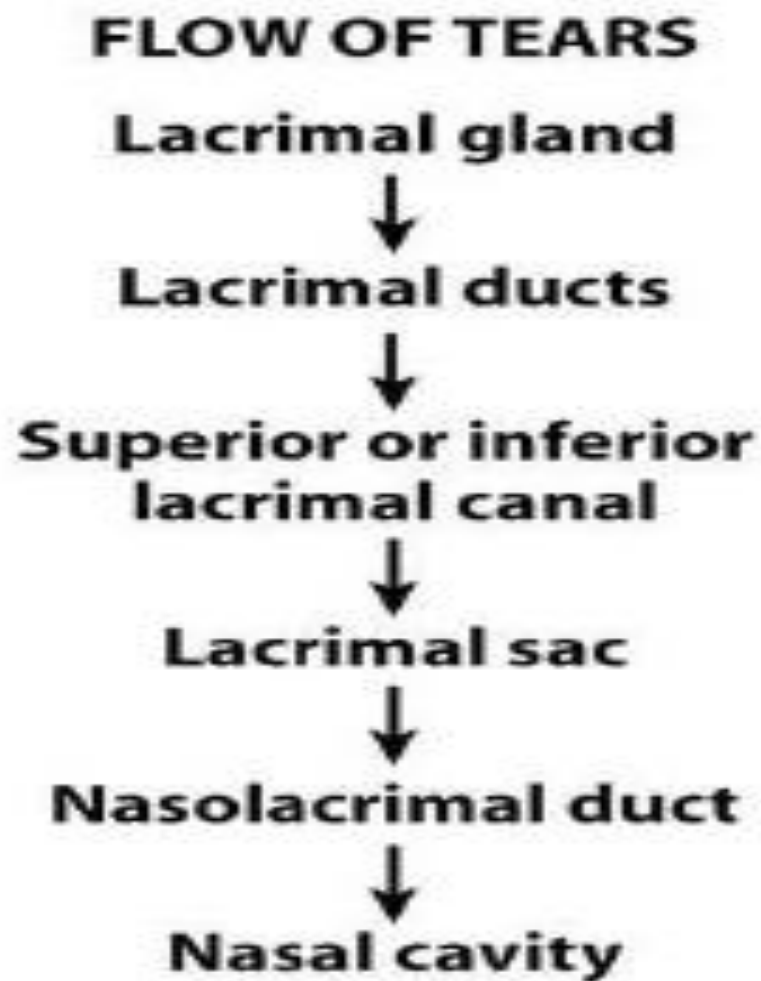It consists of:



**Anterior view of the lacrimal apparatus**

Figure 16-7b Anatomy and Physiology: From Science to Life  
© 2006 John Wiley & Sons







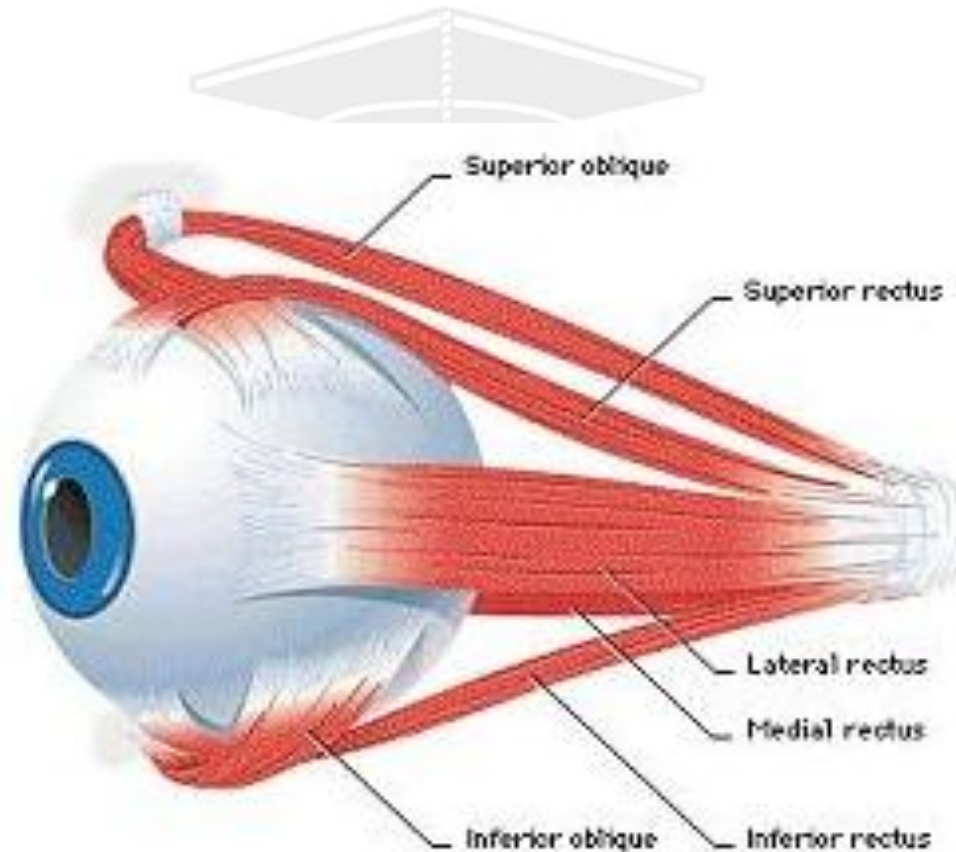
# The extraocular muscles

## The 4 Recti Muscles:

1. Superior Rectus,
2. Inferior Rectus,
3. Lateral (Ext) Rectus,
4. Medial (Int.) Rectus.

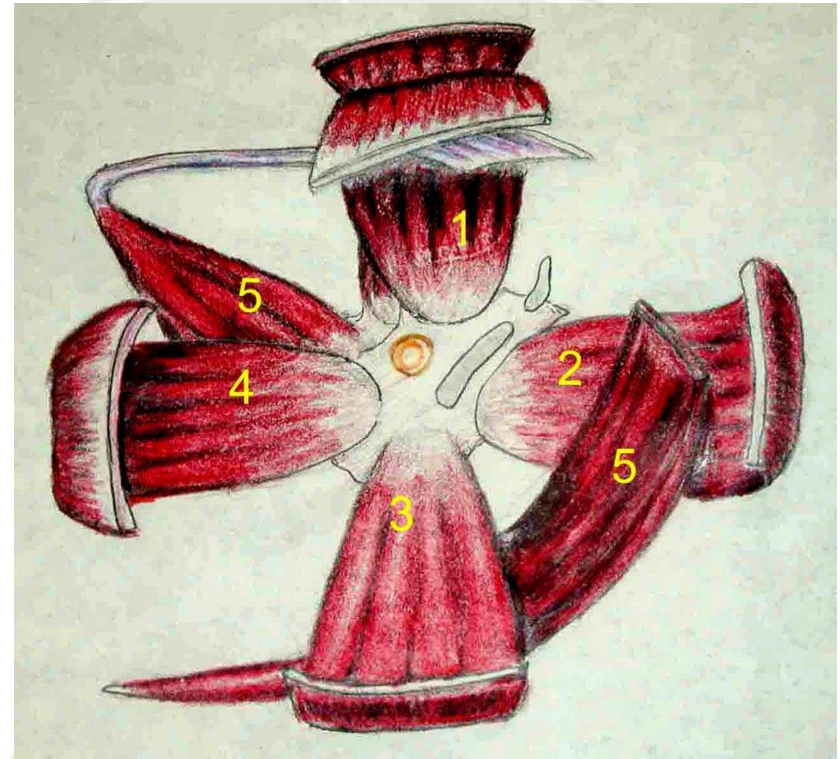
## The 2 Oblique Muscles:

1. Superior Oblique,
2. Inferior Oblique





- All of the extraocular muscles (1,2,3,4,6) – **with the exception of the inferior oblique**, arises from the apex of the orbit – conic structure called annulus of Zinn
- The inferior oblique (5) arise from the lacrimal fossa in the nasal portion of the bony orbit.



<http://www.images.missionforvisionusa.org/anatomy/index4.html>

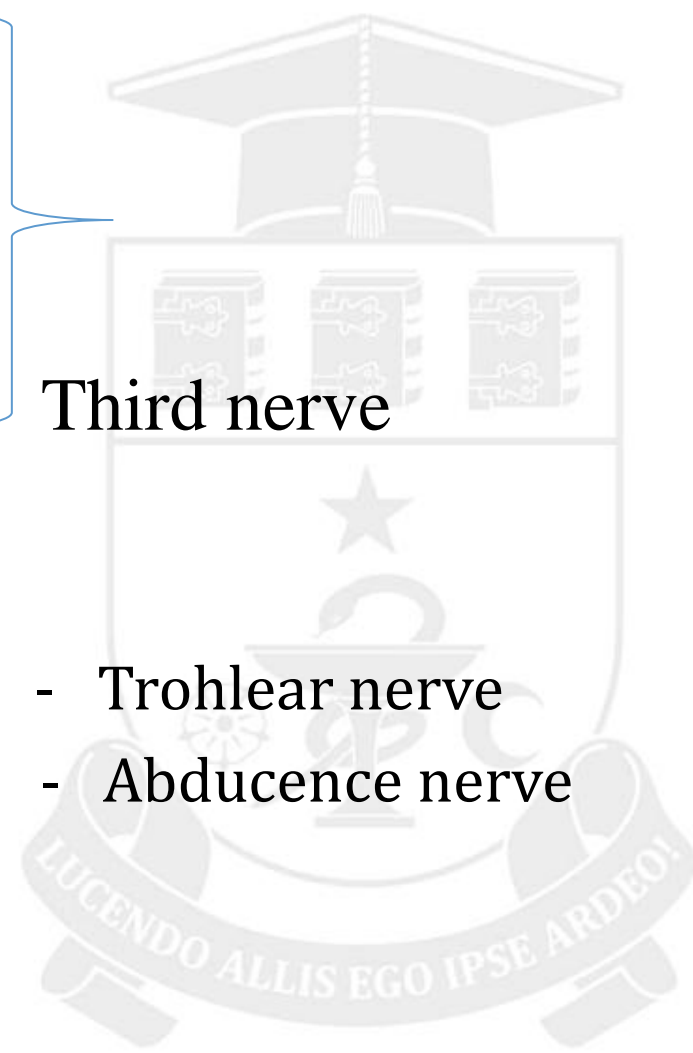


# INNERVATION

- the medial rectus,
- superior rectus,
- inferior rectus
- inferior oblique.
- levator palpebri.
- superior oblique
- Lateral rectus

Third nerve

- Trochlear nerve
- Abducence nerve





# References:

1. C. Nicula; Ophthalmology University of Medicine and Pharmacy "Iuliu Hatieganu, 2011
2. Jack J. Kansky; Brad Bowling *Clinical ophthalmology. A systemic approach.*; 2011.
3. Bruce James, Chris Chew, Anthony Bron *Ophthalmology* Blackwell Publishing; 2007. Bruce James; Cris Chew; Anthony Bron *Ophthalmology* 2007, Blackwell Publishing.
4. American Academy of Ophthalmology. Basic and Clinical Science Course Section 7, 2006-2007.
5. Kanski J.J *Clinical Ophthalmology*. Butterworth-Heinemann. 2003.
6. Ben Glasgow, M.D. *Anatomy of the Eye- A study guide for residents*. Basic Science Study List for first year ophthalmology residents. 2005.

## Websites:

1. [en.wikipedia.org/.../Category:Eye\\_anatomy](http://en.wikipedia.org/.../Category:Eye_anatomy)
2. [www.physicsclassroom.com/.../u14l6a.cfm](http://www.physicsclassroom.com/.../u14l6a.cfm)
3. [www.eyeatlas.com/contents.htm](http://www.eyeatlas.com/contents.htm)
4. [en.wikibooks.org/.../Anatomy\\_of\\_the\\_Eye](http://en.wikibooks.org/.../Anatomy_of_the_Eye)
5. [www.opthobook.com/chapters/anatomy](http://www.opthobook.com/chapters/anatomy)

