



UNIVERSITATEA DE STAT DE MEDICINĂ ȘI FARMACIE
„NICOLAE TESTEMIȚANU” DIN REPUBLICA MOLDOVA

Catedra Oftalmologie


EYE ADNEXA DISEASES

Associate Professor
ALA PADUCA



Aim

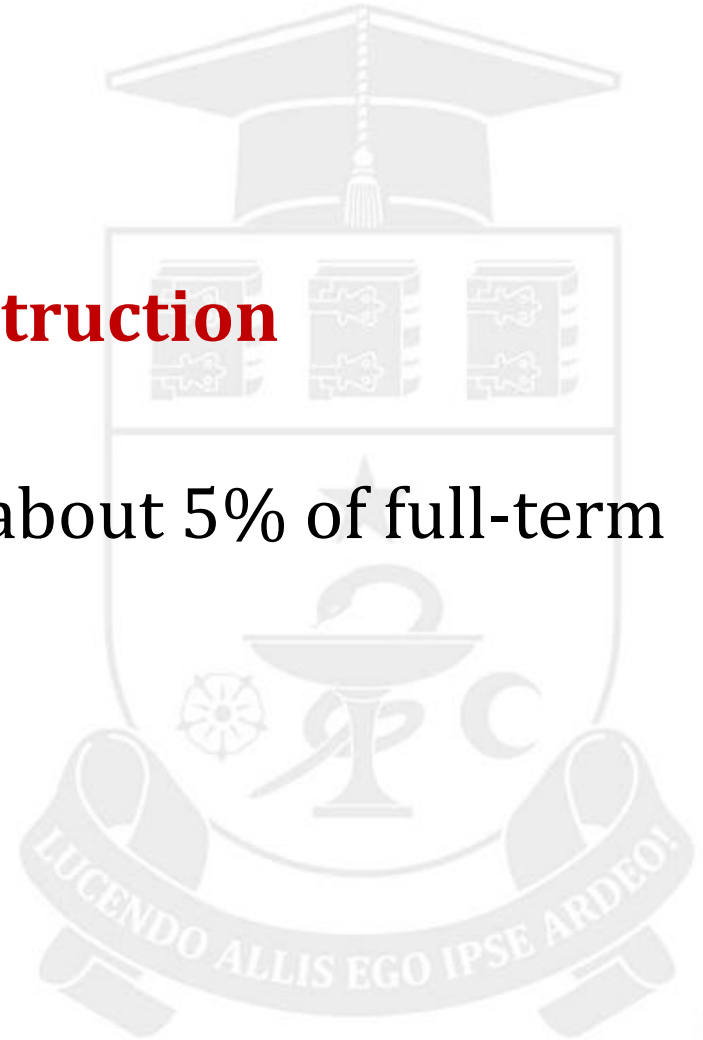
- to provide students with a thorough grounding in the major eyelids, conjunctiva and lacrimal system diseases





PATHOLOGY OF THE LACRIMAL SYSTEM

- 1. Dacrioadenitis**
- 2. Nasolacrimal duct obstruction (dacriocystitis):**
 - Congenital (ocurs in about 5% of full-term newborns)
 - Adult





Dacryoadenitis is inflammation of the lacrimal glands

- Acute dacryoadenitis is most commonly due to viral or bacterial infection. Common causes include Epstein-Barr virus, staphylococcus, and gonococcus.
- Chronic dacryoadenitis is usually due to noninfectious inflammatory disorders (ex. sarcoidosis, thyroid eye disease)



SYMPTOMS

- **Swelling** of the outer portion of the upper lid (the superotemporal orbit) with **redness** of the tissues surrounding these glands.
- Pain in the area of swelling
- Excess tearing or discharge
- Swelling of lymph nodes in front of the ear
- Additional eye symptoms: - photophobia,
- tearing, or
- a foreign body sensation may also occur.

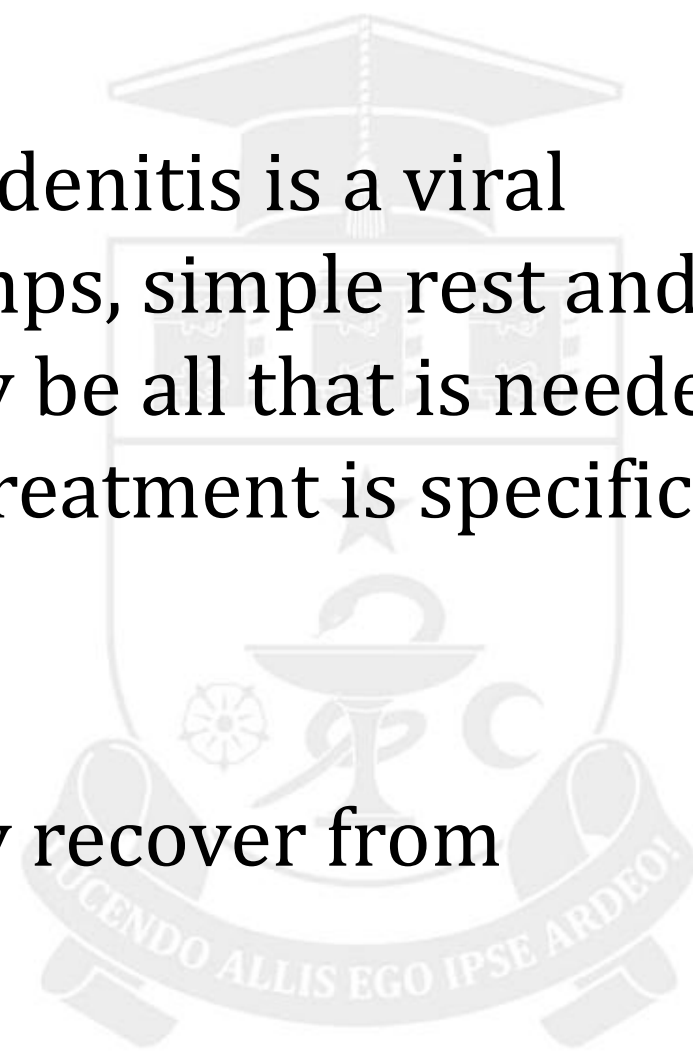


Treatment

- If the cause of dacryoadenitis is a viral condition such as mumps, simple rest and warm compresses may be all that is needed. For other causes, the treatment is specific to the causative disease.

Prognosis

- Most patients will fully recover from dacryoadenitis.

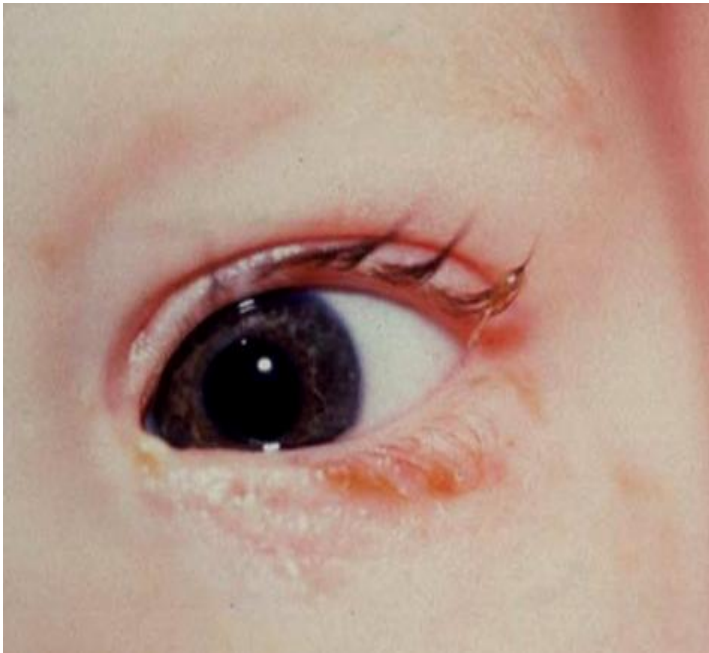



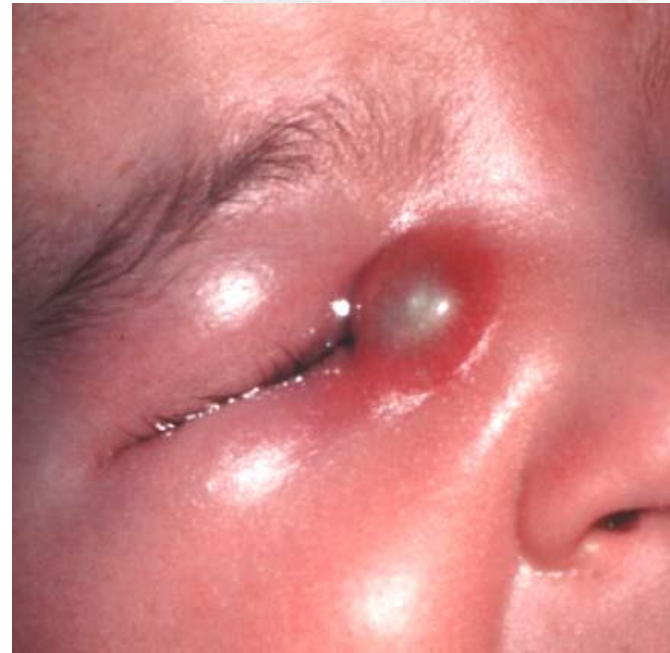Congenital nasolacrimal duct obstruction

Caused by delayed canalization (a thin mucosal membrane at the lower end of NLD)

SIGNS: On pressure over the lacrimal sac produces reflux of purulent material from punctum



- Epiphora (Tearing)
- Muroid or mucopurulent discharge



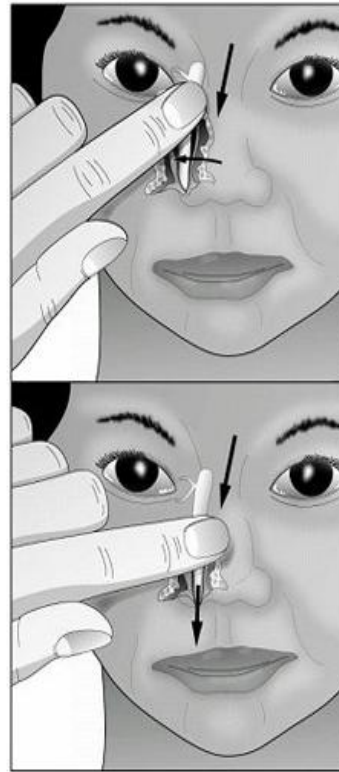
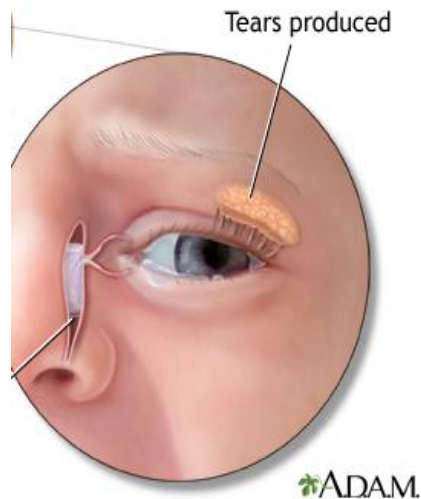
- acute dacryocystitis

Kansky



Treatment of congenital nasolacrimal duct obstruction

- Digital massage of nasolacrimal duct and antibiotic drops 4 times daily
- Improvement by age 2-3 months in 95% of cases



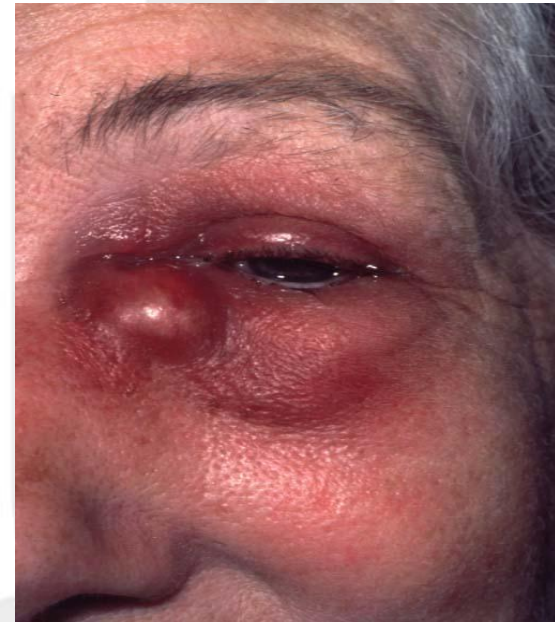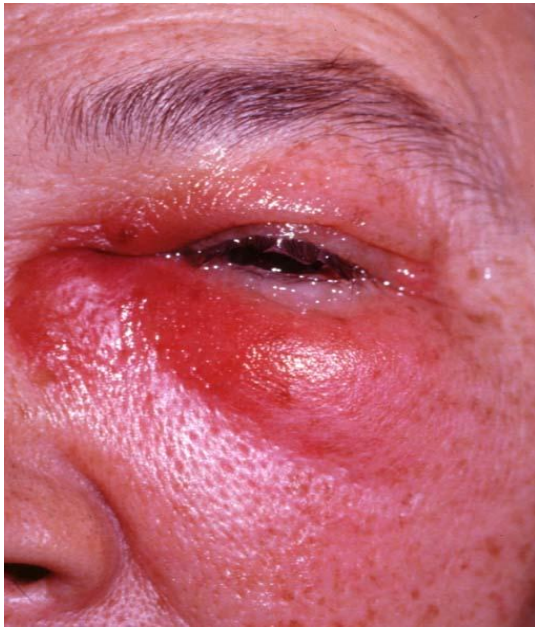- If no improvement - probe at 12-18 months
- Results - 90% cure by first probing and 6% by second



Adult acute dacryocystitis

Usually secondary to nasolacrimal duct obstruction.

It is most commonly caused by *Staphylococcus aureus* and *Streptococcus pneumoniae*



- Pain, swelling, redness over the lacrimal sac at medial canthus
- Tearing, crusting, fever
- Digital pressure over the lacrimal sac may extrude pus through the punctum
- In chronic cases, tearing may be the only symptom

- May develop into abscess
- The most common complication is corneal ulceration

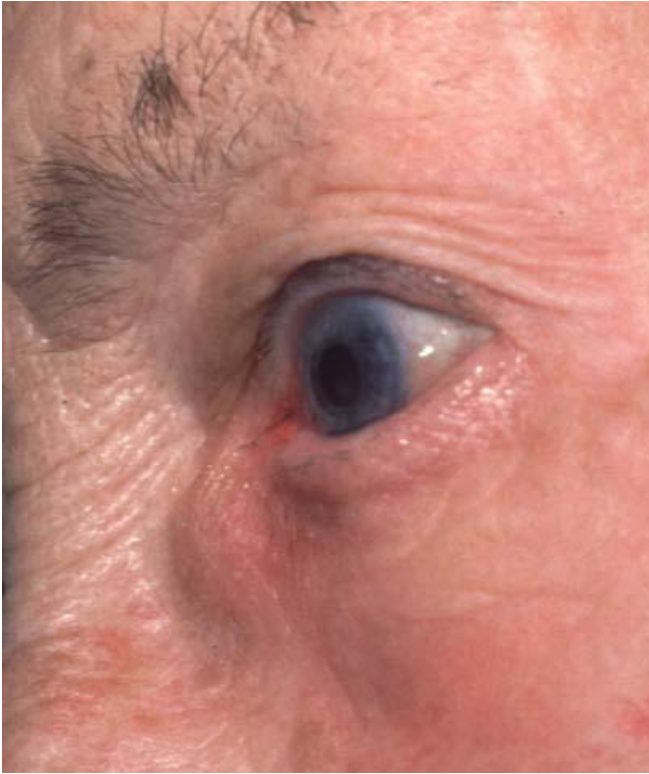
Treatment

- Systemic antibiotics and warm compresses
- DCR after acute infection is controlled

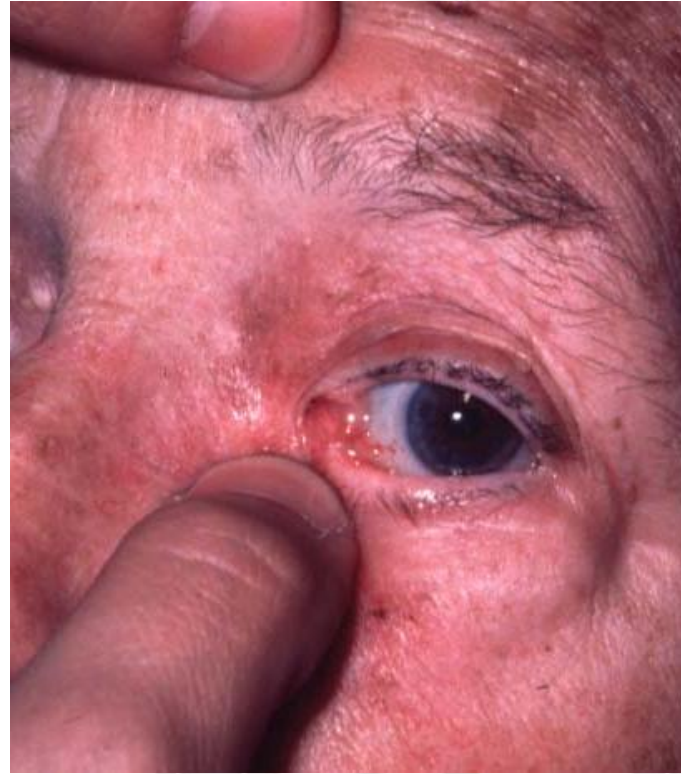

Chronic dacryocystitis: catarrhal and suppurative

Epiphora and chronic or recurrent unilateral conjunctivitis



In chronic cases, tearing may be the only symptom
Painless swelling at medial canthus



Expressed mucopurulent material through the punctum on digital pressure over the sac

Treatment - DCR



DIAGNOSIS

1. Examination:

1. Inspection (slit lamp).
2. Palpation of lacrimal sac and regurge test.
3. DDT.

2. Propping & irrigation.

3. Jones dye test: 1ry. & 2ry.

4. Radiological ex.

5. Nasal examination.



ABNORMALITIES OF EYELIDS POSITION

- ✓ Ectropion
- ✓ Entropion
- ✓ Ptosis






ECTROPION AND ENTROPION

1. Ectropion

- Involutional
- Cicatricial
- Paralytic
- Mechanical

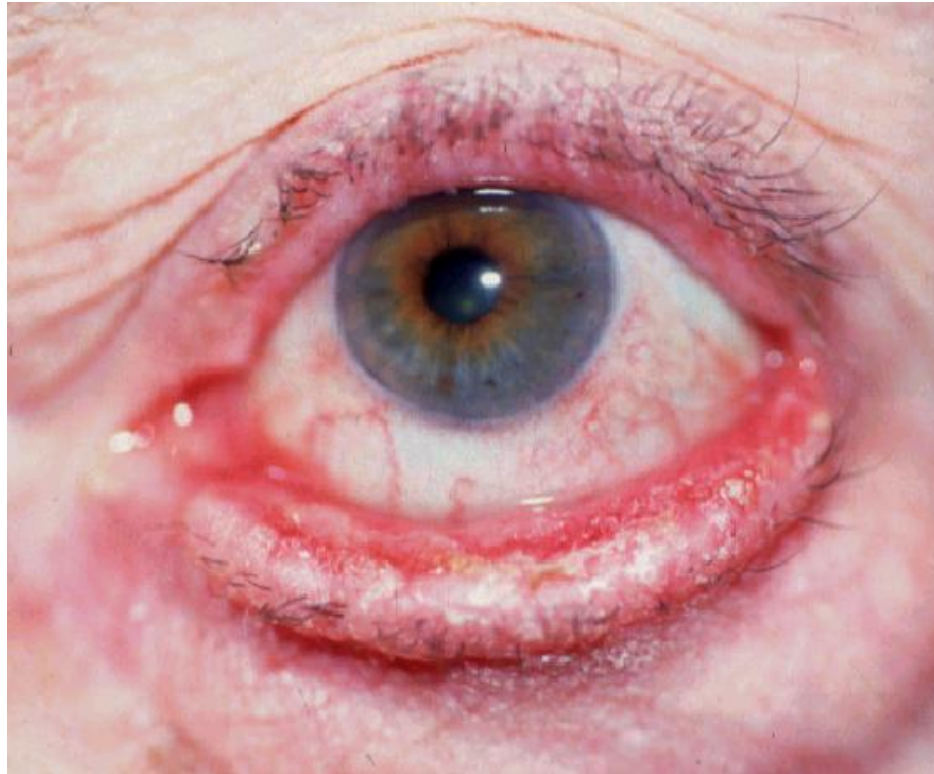2. Entropion

- Involutional
- Cicatricial
- Congenital





Involucional

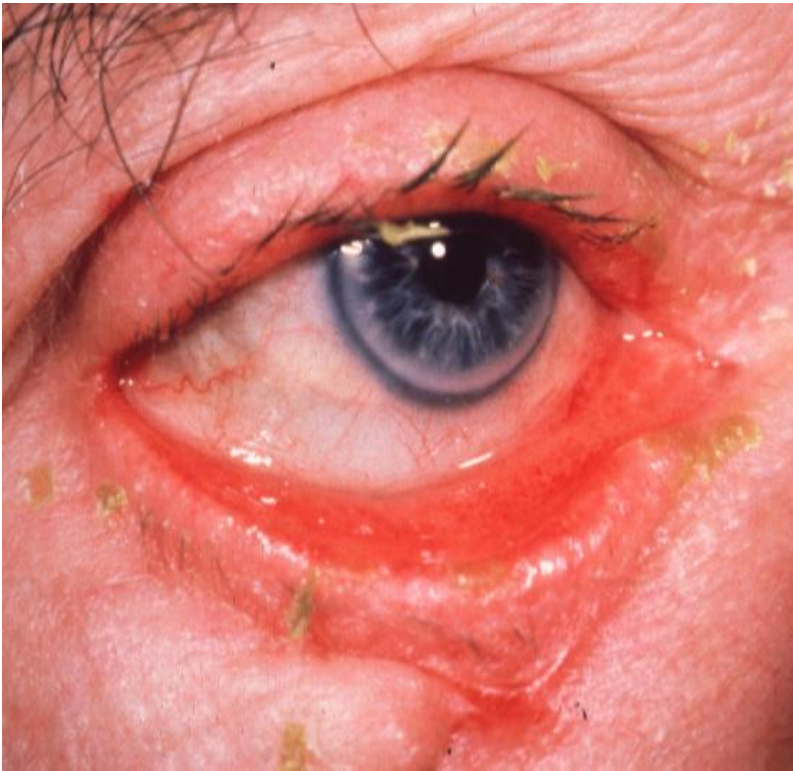

- Affects lower lid of elderly patients
- May cause chronic conjunctival inflammation and thickening

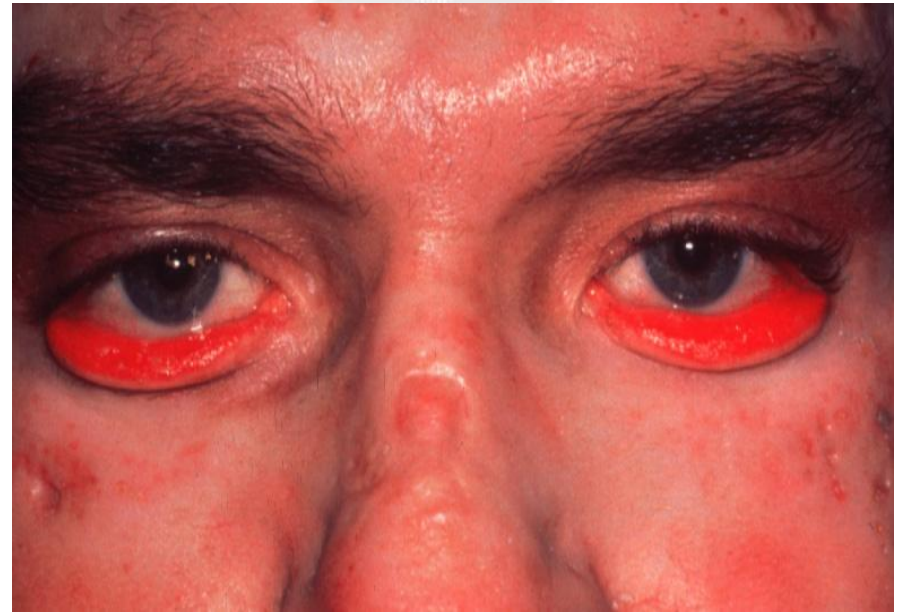

Causes of cicatricial ectropion

- Contracture of skin pulling lid away from globe
- Unilateral or bilateral, depending on cause



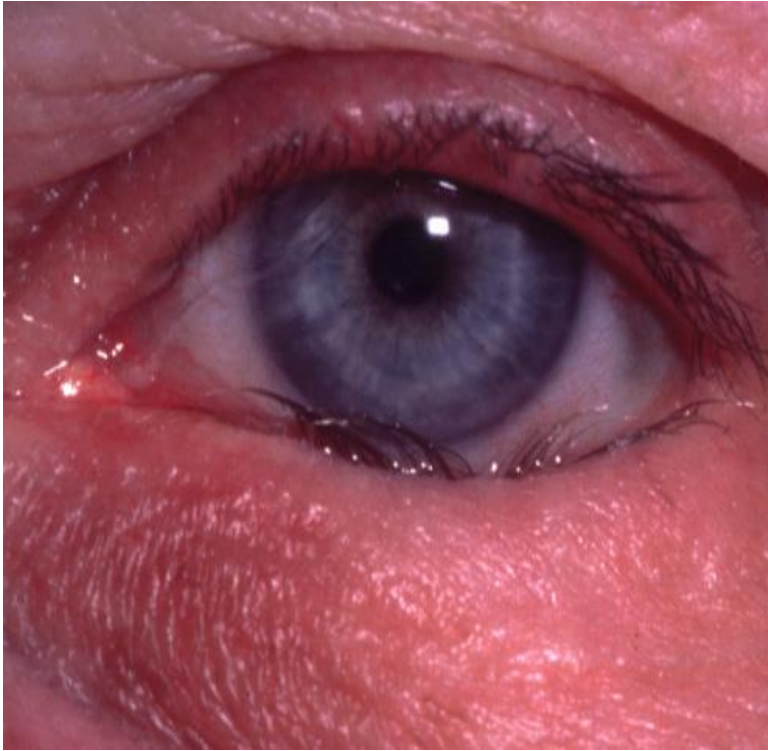
Unilateral ectropion due to traumatic scarring



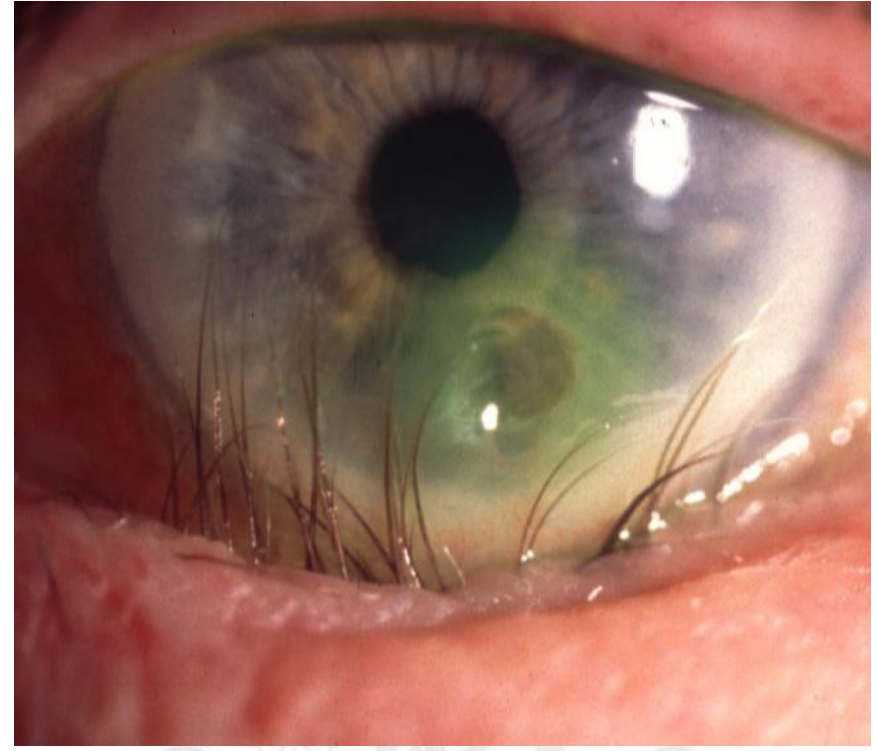
Bilateral ectropion due to severe dermatitis




Involucional entropion



Affects lower lid because upper lid has wider tarsus and is more stable



If longstanding may result in corneal ulceration





Classification

- *Neurogenic ptosis* which includes [oculomotor nerve palsy](#), [Horner's Syndrome](#),
- *Myogenic ptosis* which includes [myasthenia gravis](#), simple congenital ptosis
- *Aponeurotic ptosis* which may be involutional or post-operative.
- *Mechanical ptosis* which occurs due to edema or tumors of the upper lid
- *Neurotoxic ptosis*

1.Acquired ptosis is most commonly caused by aponeurotic ptosis

2.Congenital ptosis



Treatment

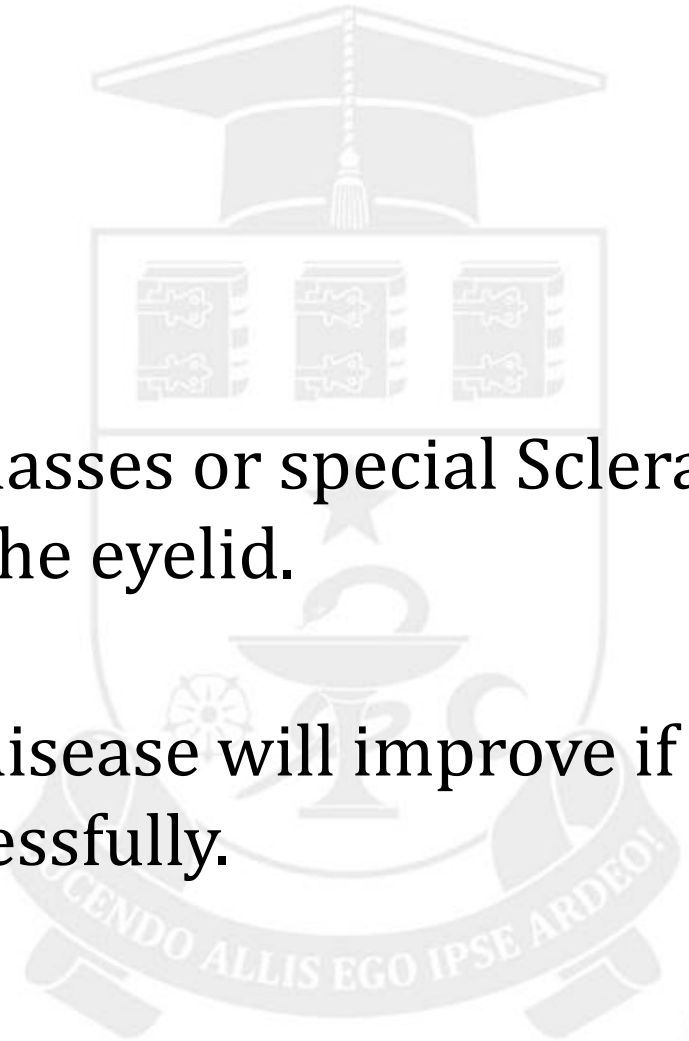
Surgical procedures:

Levator resection

Frontalis sling operation

Non-surgical modalities: glasses or special Scleral contact lenses to support the eyelid.


Ptosis that is caused by a disease will improve if the disease is treated successfully.





INFLAMMATION OF THE EYELIDS

- ✓ Blepharitis
- ✓ Hordeolum
- ✓ Chalasion





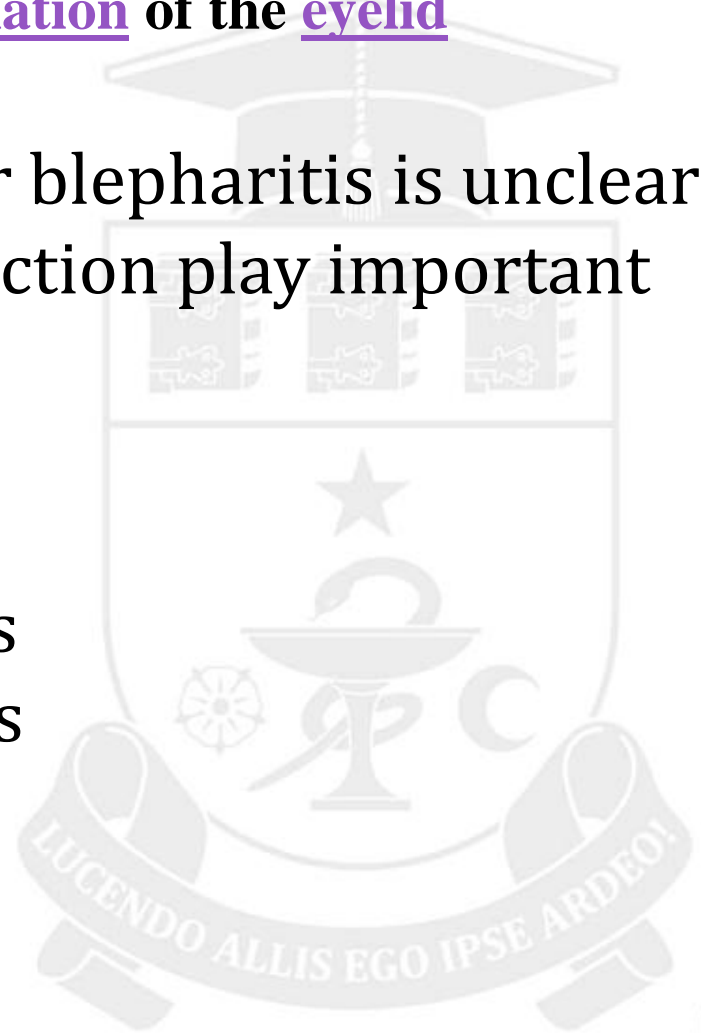MARGINAL BLEPHARITIS

chronic inflammation of the eyelid

The pathogenesis of anterior blepharitis is unclear although staphylococcal infection play important roles

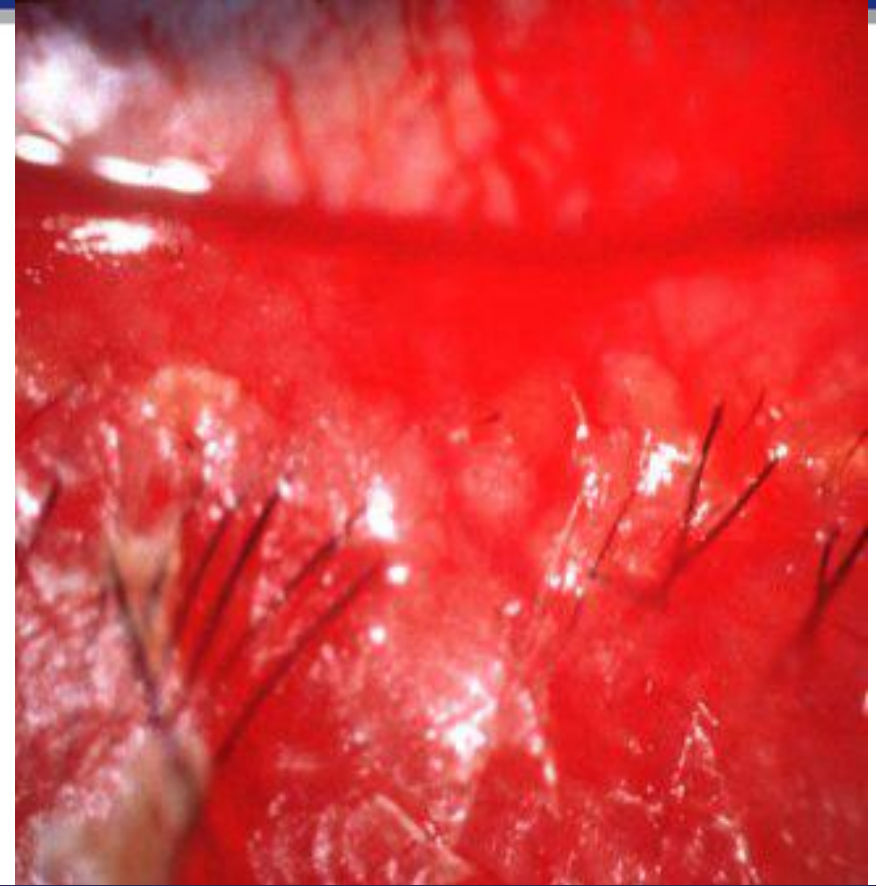
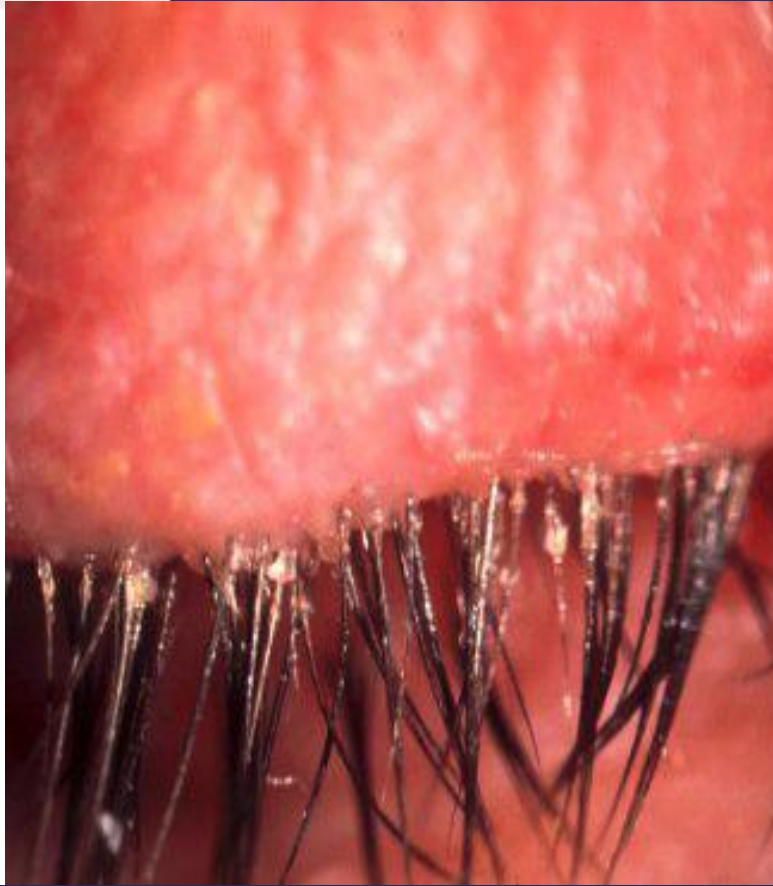SYMPTOMS:

- ✓ Redness of the lid margins
- ✓ Crusting at the lid margins
- ✓ Foreign body sensation
- ✓ Burning
- ✓ Mild photophobia





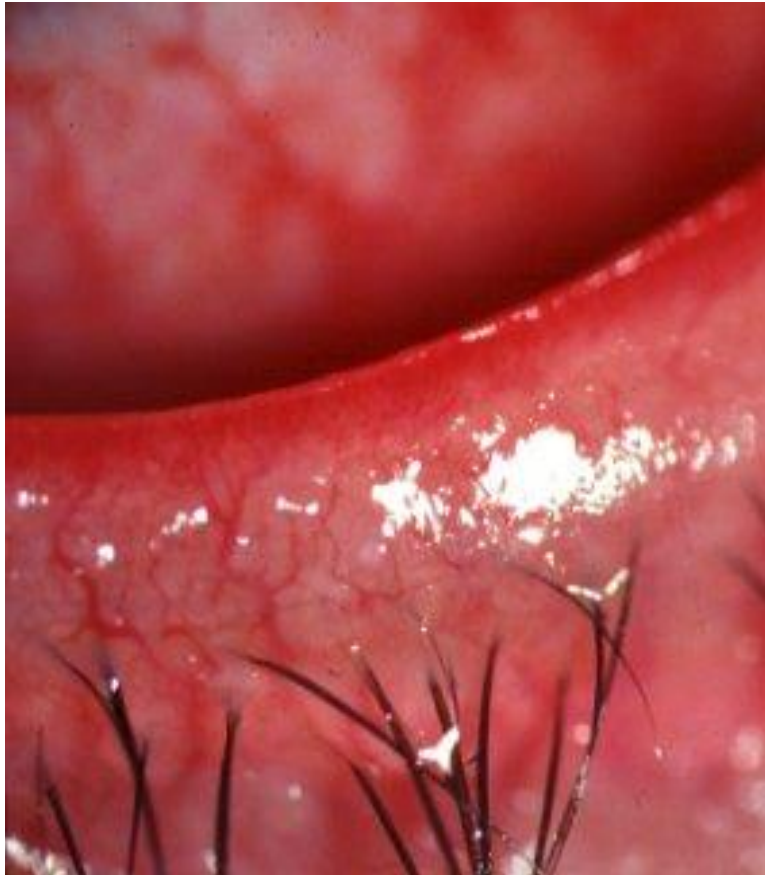
Staphylococcal blepharitis



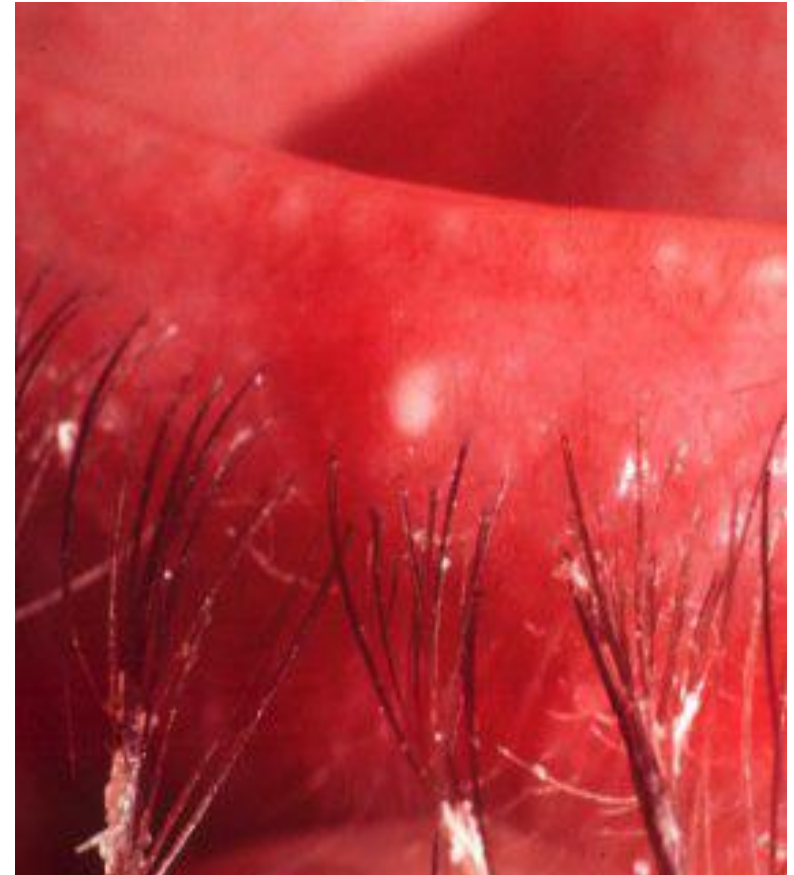
- Chronic irritation worse in mornings
- Scales around base of lashes (collarettes)
- Hyperaemia of anterior lid margin



Seborrheic blepharitis



- Hyperaemia of lid margin

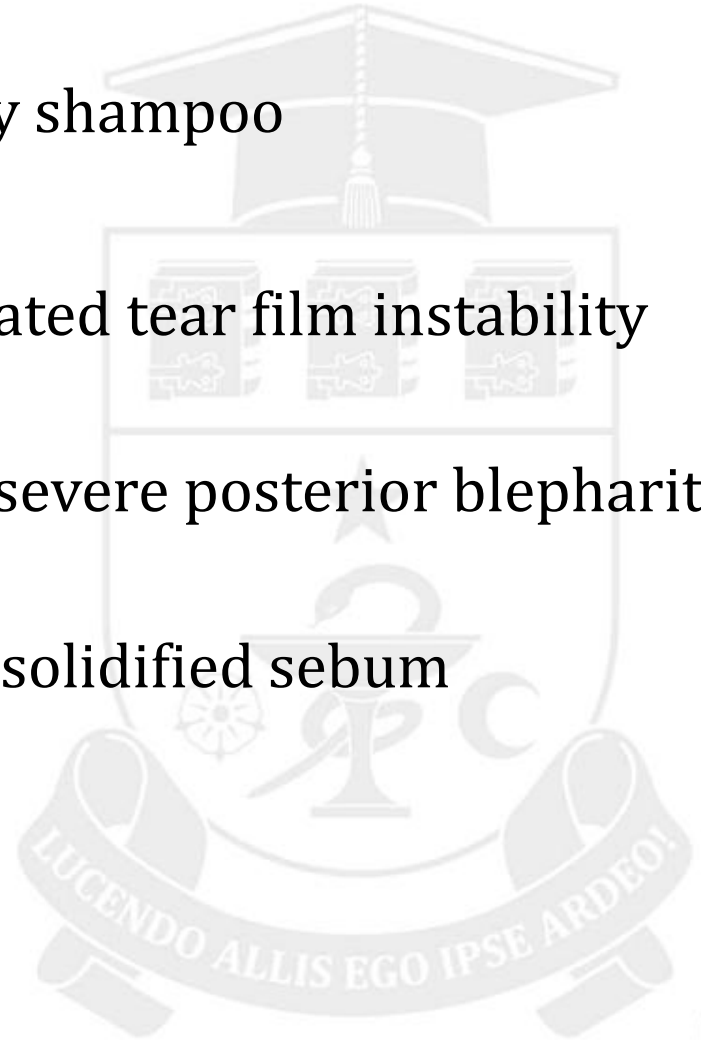


- Greasy scales
- Lashes stuck together



Treatment of Chronic Blepharitis

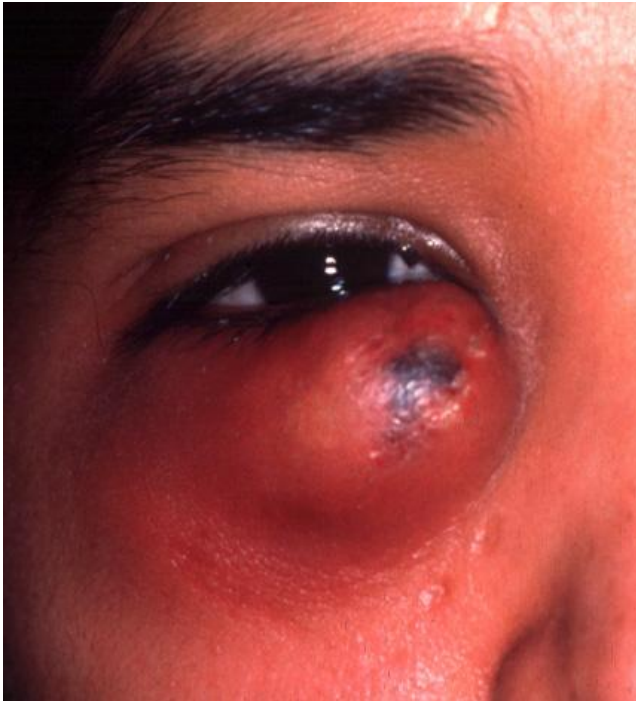1. **Lid hygiene** - with 25% baby shampoo
2. **Tear substitutes** - for associated tear film instability
3. **Systemic tetracyclines** - for severe posterior blepharitis
4. **Warm compresses** - to melt solidified sebum in posterior blepharitis





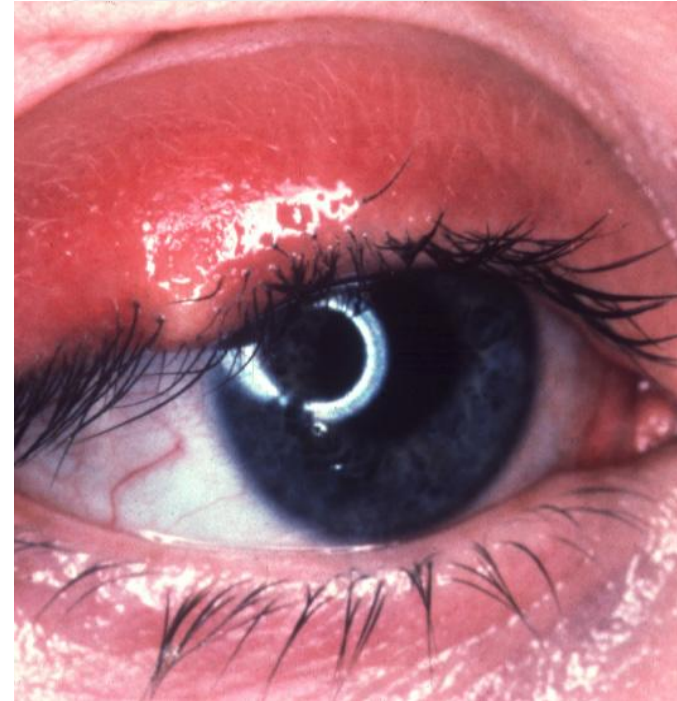Acute hordeola

Internal hordeolum (acute chalazion)



- *Staph.* abscess of meibomian glands
- Tender swelling within tarsal plate
- May discharge through skin or conjunctiva

External hordeolum



- *Staph.* abscess of lash follicle and associated gland of Zeis or Moll
- Tender swelling at lid margin
- May discharge through skin



Internal Hordeolum

- Internal styes aren't contagious. You can't catch a stye from someone else. However, you can spread bacteria from an internal stye to your eye. This can happen if you rub, pop, or squeeze a stye.
- Internal styes are usually more painful than external styes. They may also last longer. A serious internal stye can sometimes become chronic and return after it heals. It can also cause a hardened cyst, or chalazion, on the inside of your eyelid.
- According to a medical review, if you get internal styes often you may be a carrier of Staphylococcus bacteria in your nose passages. This can increase the risk for other nose, sinus, throat, and eye infections.



Treatment

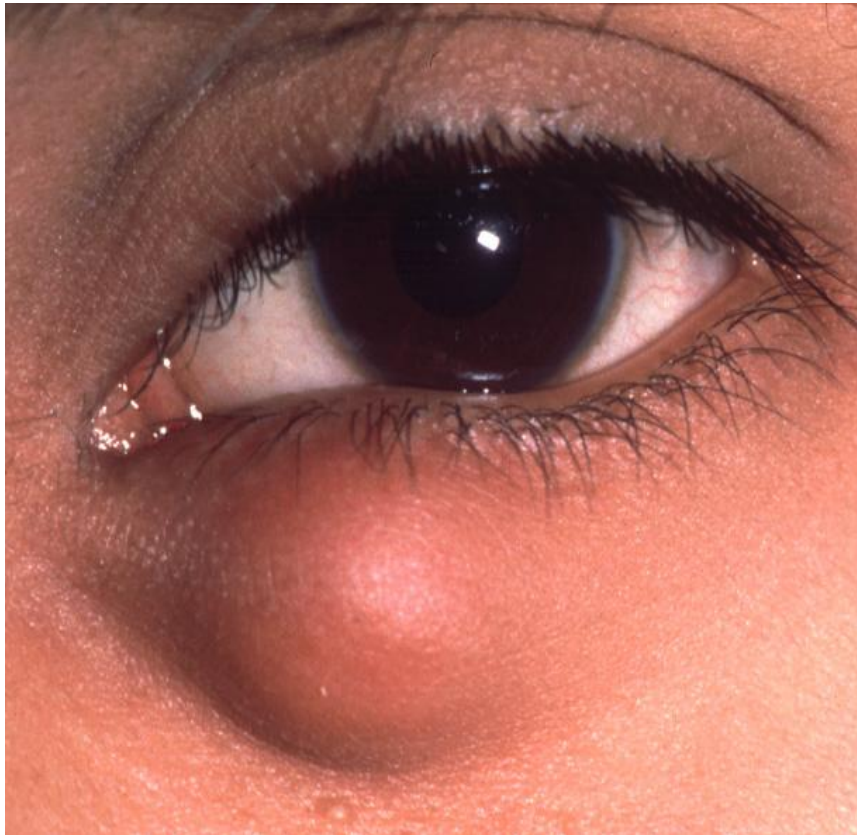
Until your sty goes away on its own, try to:

- Leave the sty alone. Don't try to pop the sty or squeeze the pus from a sty. Doing so can cause the infection to spread !!!
- Clean your eyelid. Gently wash the affected eyelid with mild soap and water.
- Place a warm washcloth over your closed eye.
- Keep your eye clean. Don't wear eye makeup until the sty has healed.
- Go without contacts lenses. Contact lenses can be contaminated with bacteria associated with a sty. If you wear contacts, try to go without them until your sty goes away.



CHALAZION (TARSAL OR MEIBOMIAN CYST)

Chronic non infective, non suppurative lipogranulomatous inflammation of Meibomian cyst.



SYMPTOMS

- Painless swelling which is gradual increasing in size
- Mild heaviness in the lid
- Watering (epiphora)
- Blurred vision occasionally



TREATMENT

➤ *Conservative treatment*

In a small, soft and recent chalazion, self-resolution may be helped by conservative treatment in the form of hot fomentation, topical antibiotic eyedrops and oral anti-inflammatory drugs.

➤ *Intralesional injection of long-acting steroid (triamcinolone)*

It cause resolution in about 50 percent cases, especially in small and soft chalazia.



BENIGN EYELIDS TUMOURS

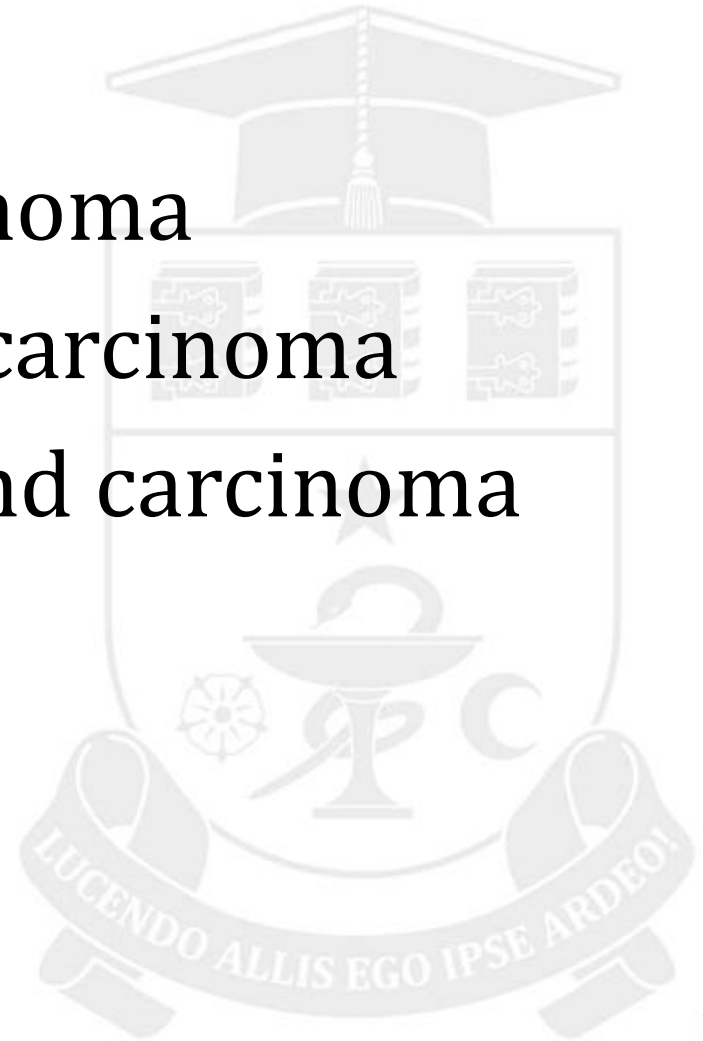
- ✓ Papilloma
- ✓ Nevus
- ✓ Haemangioma





MALIGNANT EYELID TUMOURS


1. Basal cell carcinoma
2. Squamous cell carcinoma
3. Meibomian gland carcinoma
4. Melanoma





Basal Cell Carcinoma - Important Facts


1. Most common human malignancy
2. Usually affects the elderly
3. Slow-growing, locally invasive
4. Does not metastasize
5. 90% occur on head and neck
6. Of these 10% involve eyelids
7. Accounts for 90% of eyelid malignancies





CONJUNCTIVAL INFECTIONS

1. Bacterial
2. Viral
3. Allergical

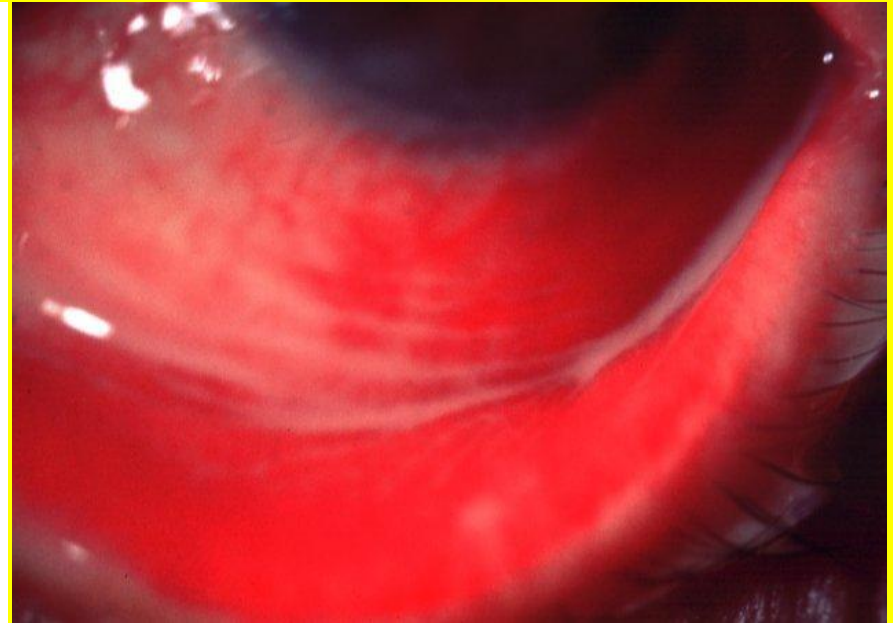




Bacterial conjunctivitis

Signs

- **conjunctival hyperemia**
- **Foreing body sensation**
- **Usually bilateral**



Mucopurulent discharge and crusted eyelids

Treatment - broad-spectrum topical antibiotics



Adenoviral Keratoconjunctivitis

1. Pharyngoconjunctival fever

- Adenovirus types 3 and 7
- Typically affects children
- Upper respiratory tract infection
- Keratitis in 30% - usually mild

2. Epidemic keratoconjunctivitis

- Adenovirus types 8 and 19
- Very contagious
- No systemic symptoms
- Keratitis in 80% of cases - may be severe

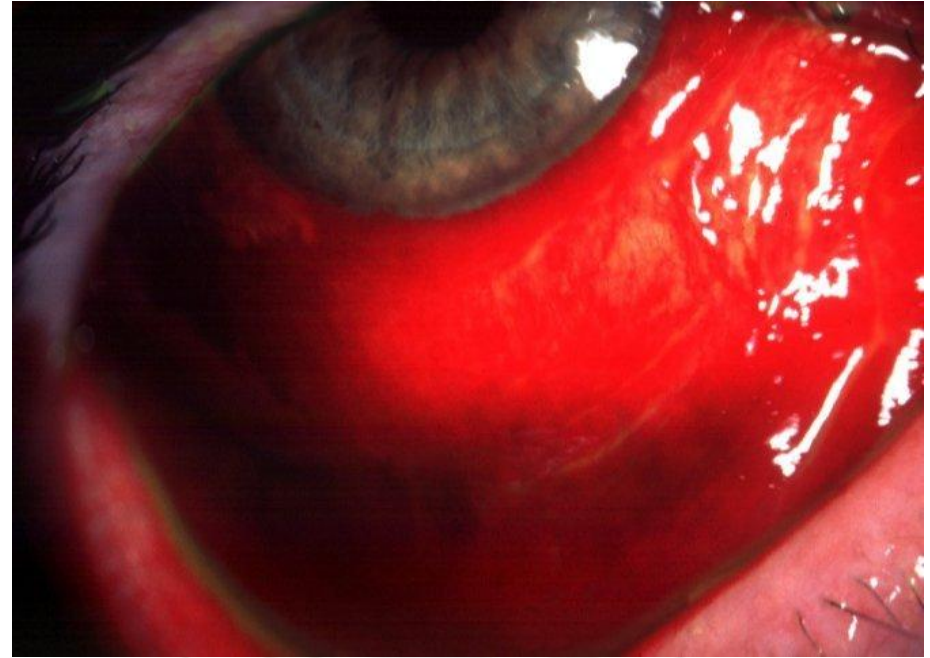


Signs of conjunctivitis

Highly contagious
Usually bilateral

Complaints:

Foreign body sensation, acute watery discharge and follicles (usually abs. of purulent secretion)




Preauricular lymphadenopathy

Treatment - symptomatic



ALLERGIC CONJUNCTIVITIS

Vernal keratoconjunctivitis





Vernal keratoconjunctivitis

Frequently associated with atopy: asthma, hay fever and dermatitis

Most commonly affects males (children and young adults)

- Usually occurs in the spring
- Bilateral Recurrent

Types

Palbebral
Limbal
Mixed

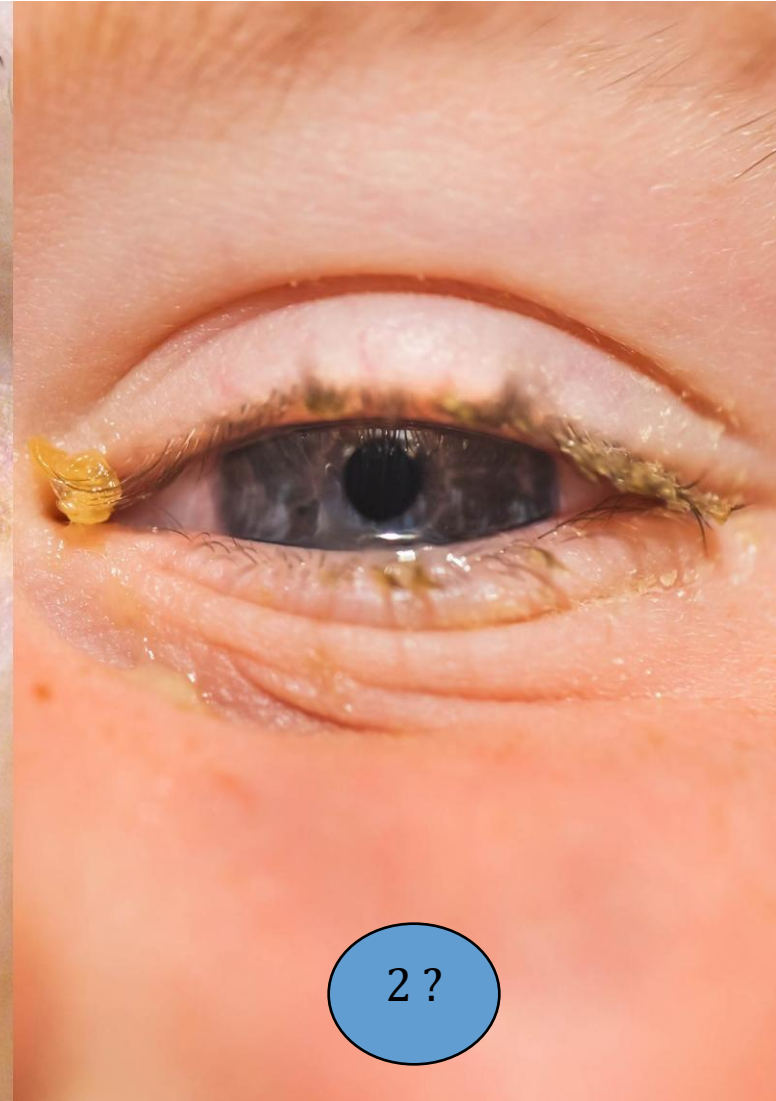
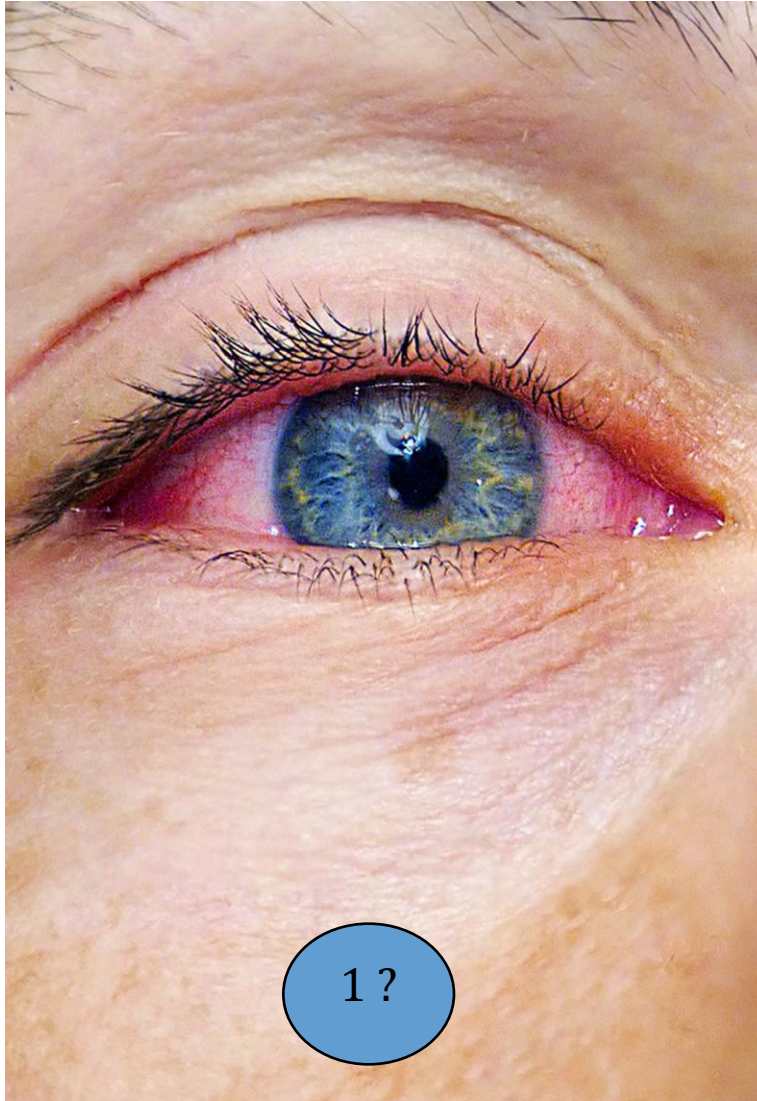Symptoms: photophobia and intense itching, mucoid discharge

Treatment

- ✓ Topical: steroid; nonsteroidal medication
- ✓ Mast cell stabilizer (cromolyn sodium) etc.
- ✓ General medication: antihistamines



Type of conjunctivitis ? 1 and 2





Bibliography

1. C. Nicula ; Ophthalmology University of Medicine and Pharmacy "Iuliu Hatieganu, 2011
2. Jack J. Kansky; Brad Bowling *Clinical ophthalmology. A systemic approach.*; 2011.
3. Bruce James, Chris Chew, Anthony Bron *Ophthalmology* Blackwell Publishing; 2007.
4. American Academy of Ophthalmology. Basic and Clinical Science Course. Lacrimal system disorders; 2017-2018.
5. www.freebookcentre.net/medical_text_books_journals/ophthalmology_ebooks_online_texts_download_1.html

