

# Patologiile vasculare ale retinei

DM DR. Angela Corduneanu

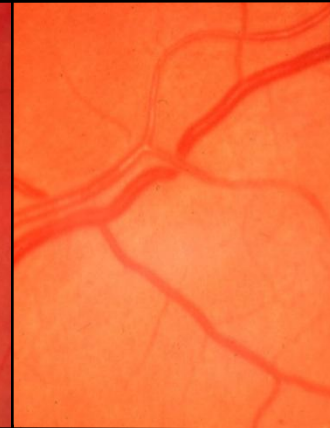
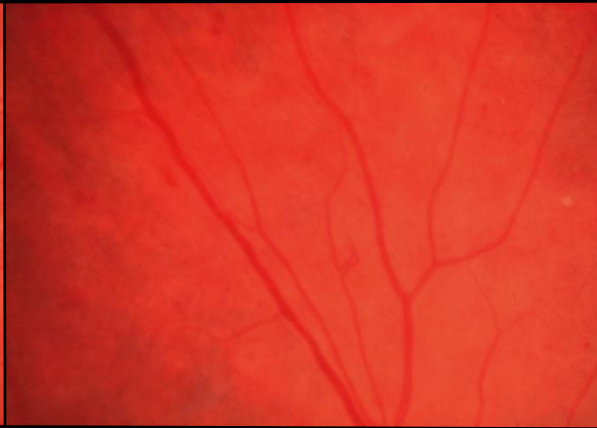
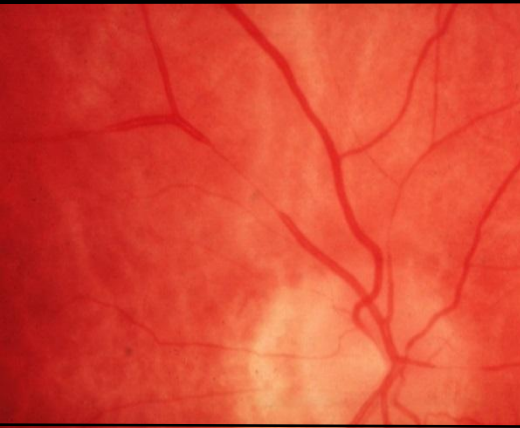# HIPERTONIA ARTERIALĂ

- Angiopatie
- Angioscleroză
- Angioretinopatie
- Neuroretinopatie

# Retinopatia hipertensivă

**Angiopatie**

**Arterioloscleroză**



Focal

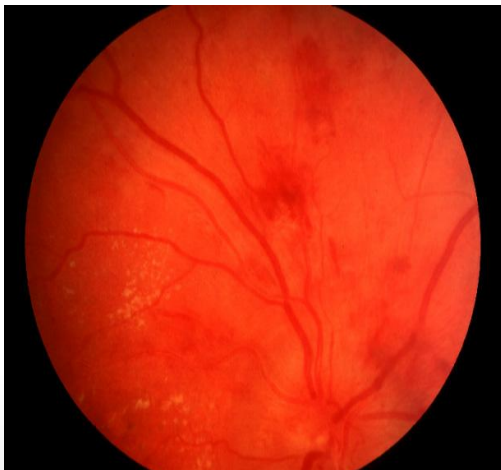**Ingustarea arteriolelor**

Generalizat

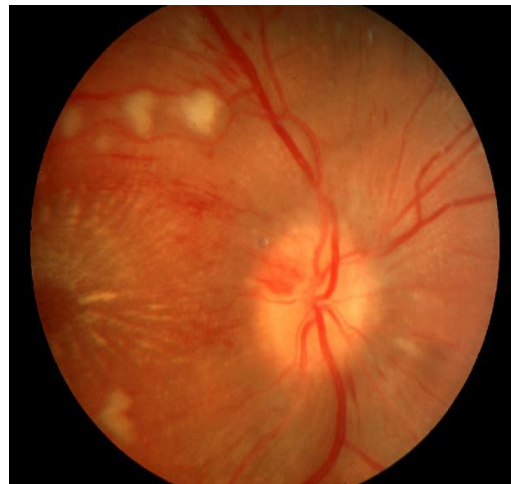(A-V schimbări sm.Salus)

**Angioretinopatie**

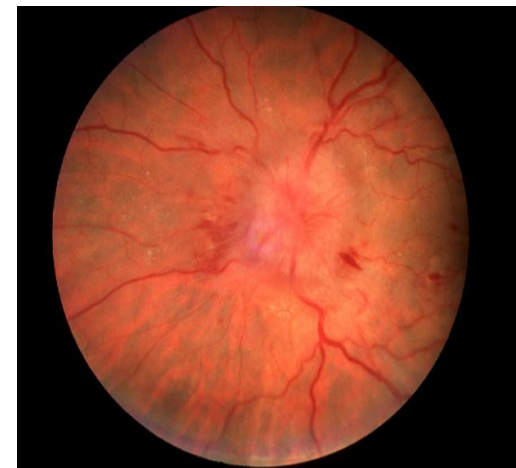**Neuroretinopatie**



**Hemoragii retiniene**

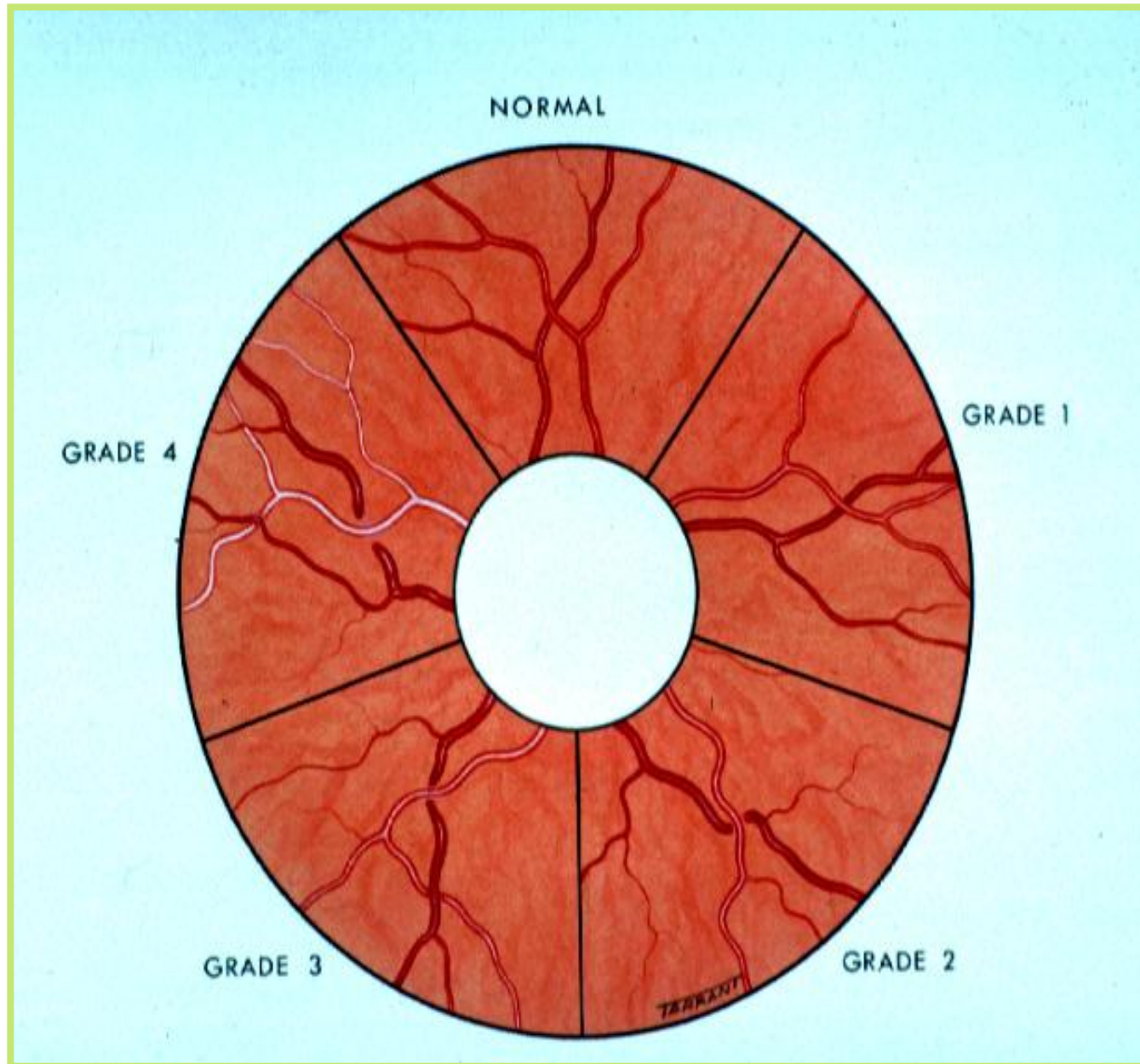


**Exudate moi “vătoase”  
și steamaculară**

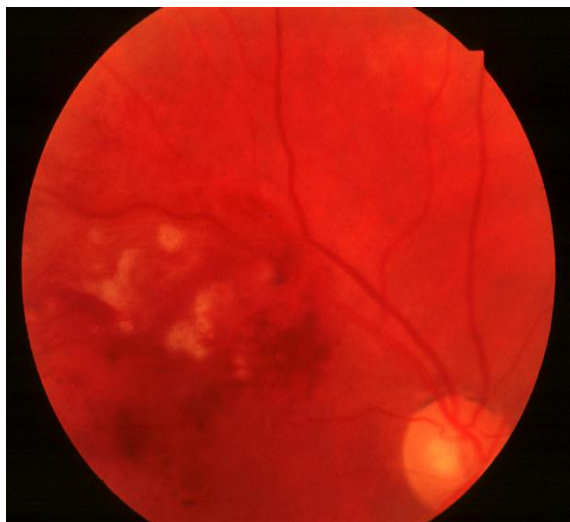

**Edemul papilei  
nervului optic**

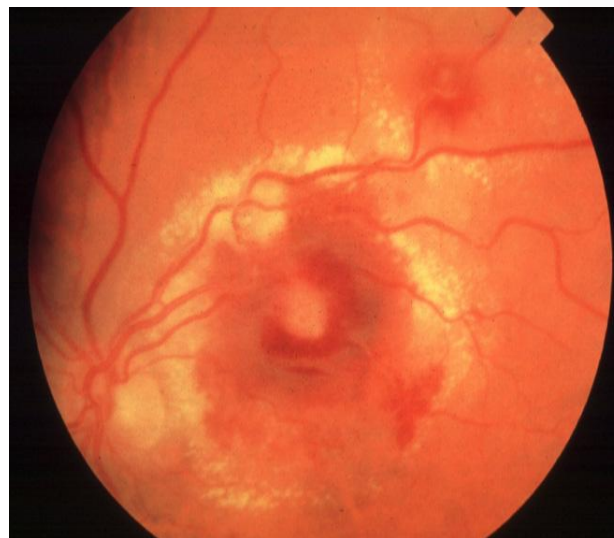# Gradele arteriolosclerozei



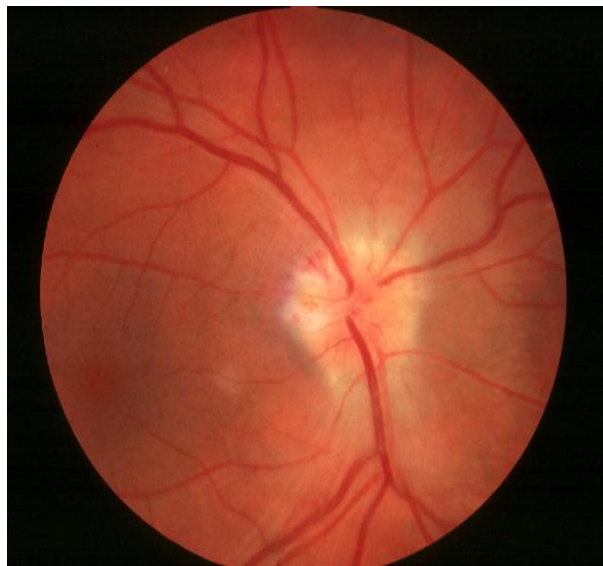
# Patologii oculare asociate hipertoniiei



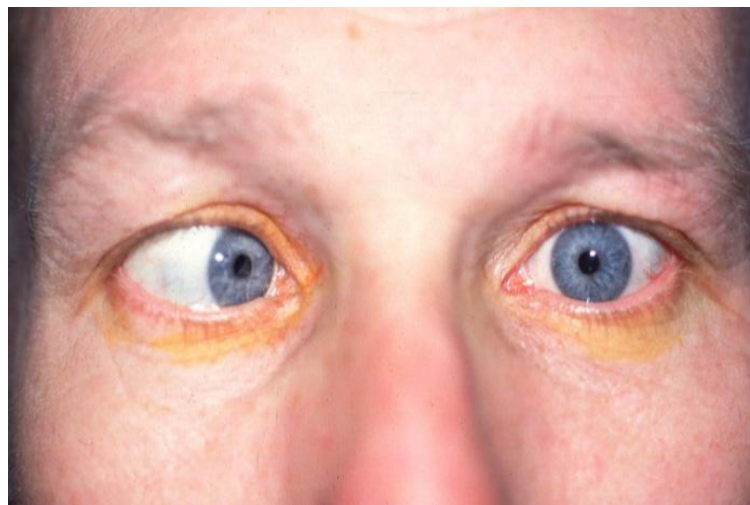**Ocluzia venoasă retiniană**



**Macroaneurizm al arteriei retiniene**



**Neuropatie anterioară ischemică**



**Paralizii ale n.Oculomotor**

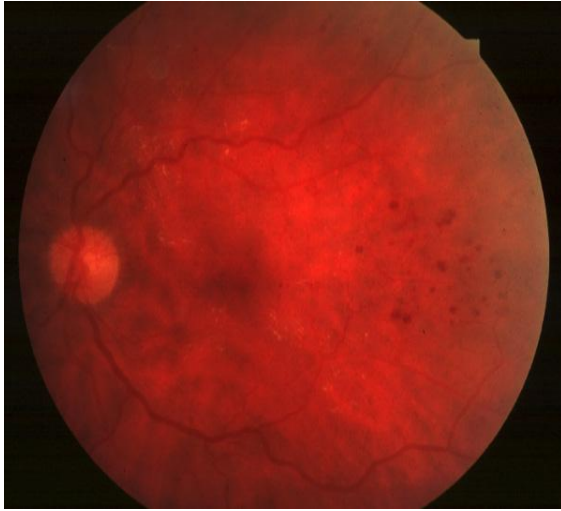
# RETINOPATIA DIABETICĂ

- Retinopatia diabetică neproliferativa
- Retinopatia diabetică preproliferativă
- Retinopatia diabetică proliferativă

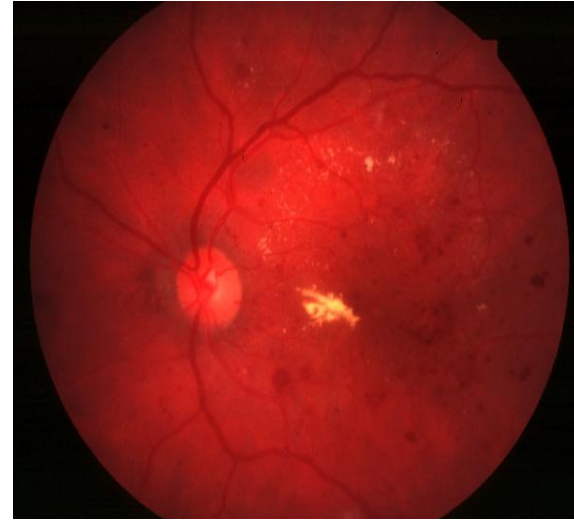# **FACTORII DE RISC**

- 1. Durata diabetului**
- 2. Control metabolic .....**
- 3. Gravitatea**
- 4. Hipertensiunea**
- 5. Patologiile renale**
- 6. Altele**
  - Obezitatea**
  - Hyperlipidaemia**
  - Fumatul**
  - Anemia**

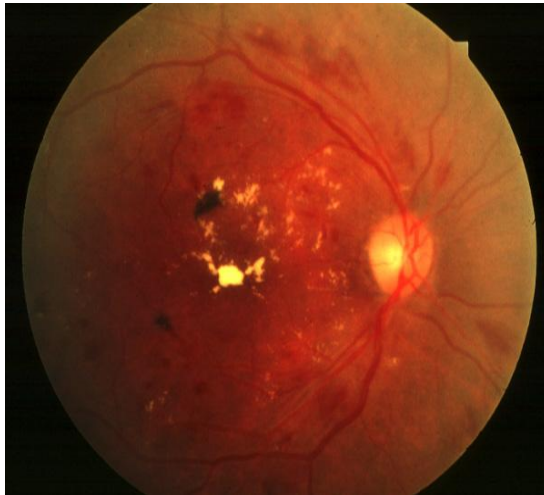# Retinopatia diabetică background



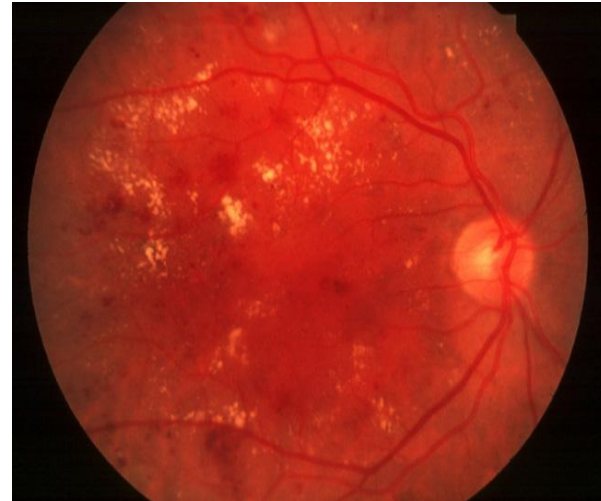**Microaneurysme**



**Hemoragii retiniene**



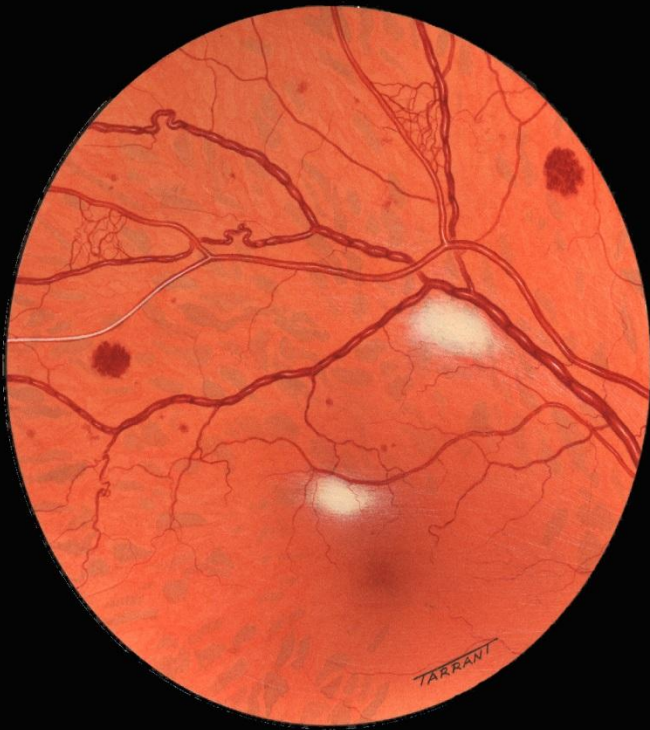**Exudate retiniene dure**



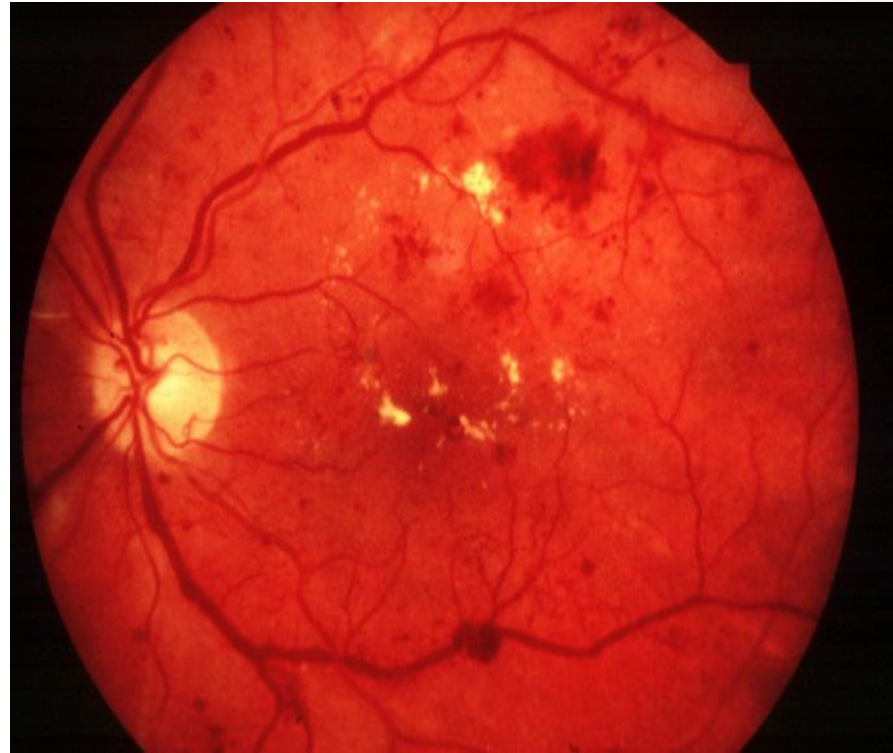**Edem retinian**



# Retinopatia diabetică Preproliferativă



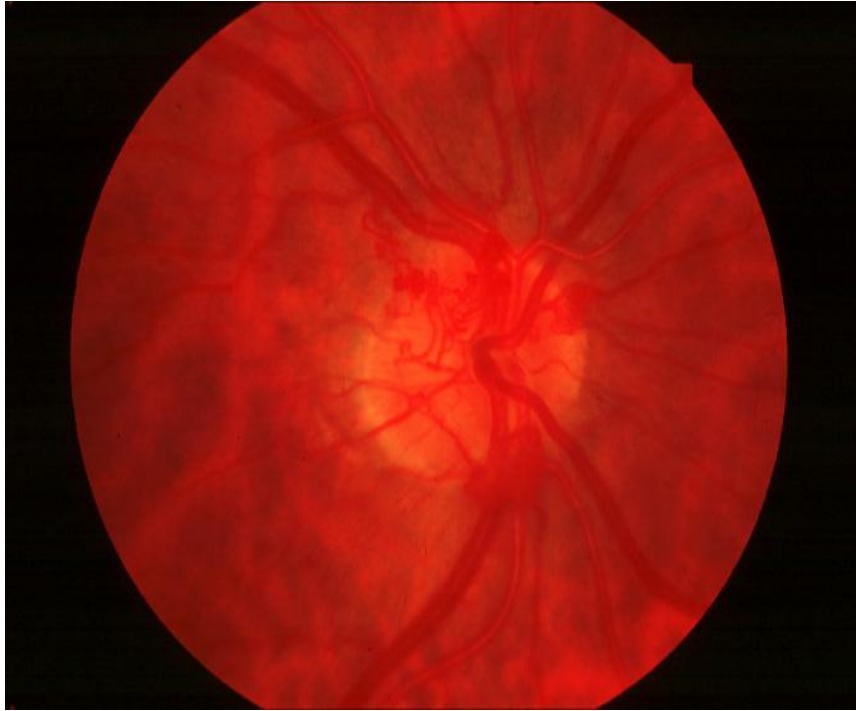- Exudate moi
- Venele de calibru neregulat



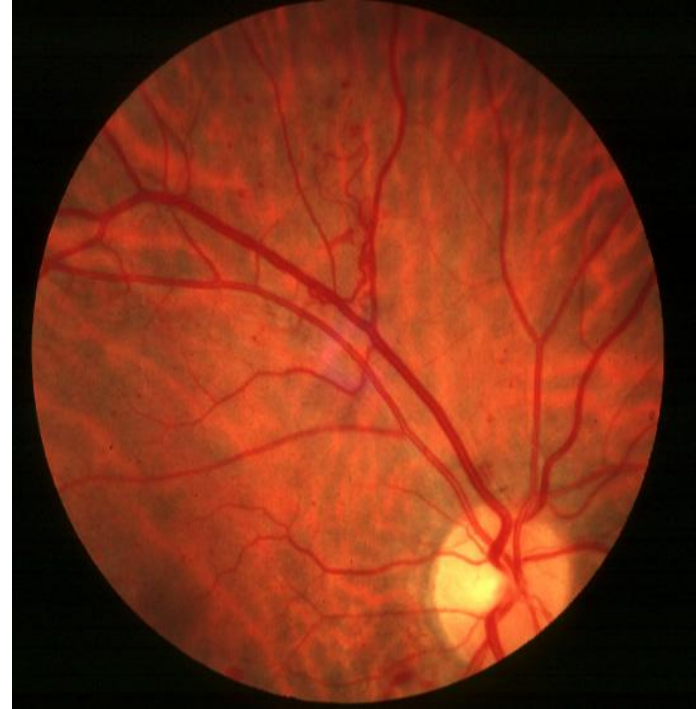- Hemoragii retiniene
- Anomalii microvasculare intraretiniene)

# Retinopatia diabetică Proliferativă

## Neovascularizatia

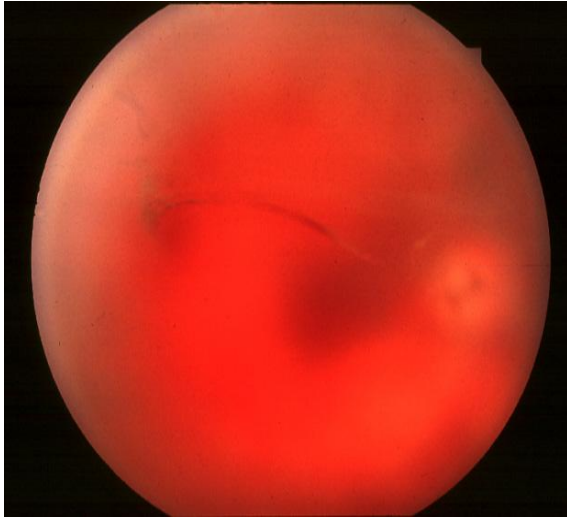


**NV discului NO**

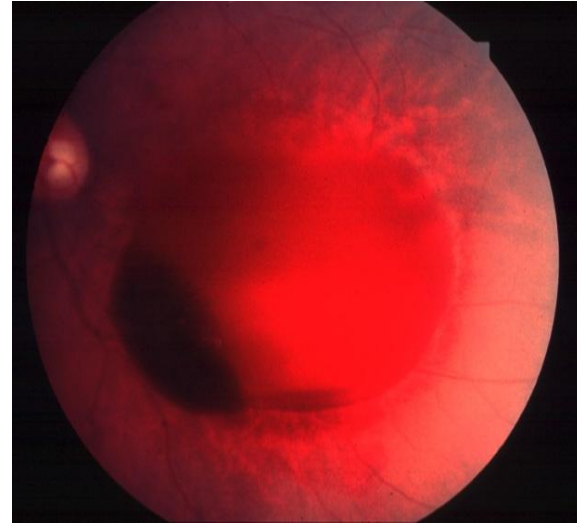


**NV retiniene**

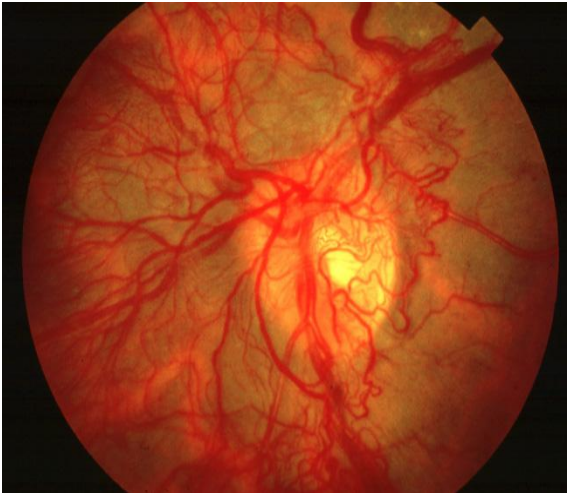# Alte complicații a RDP



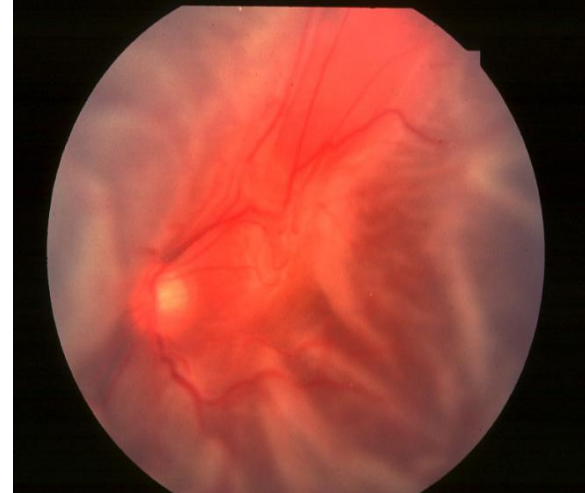**Hemoragie vitreană**



**Hemoragie densă premaculară**

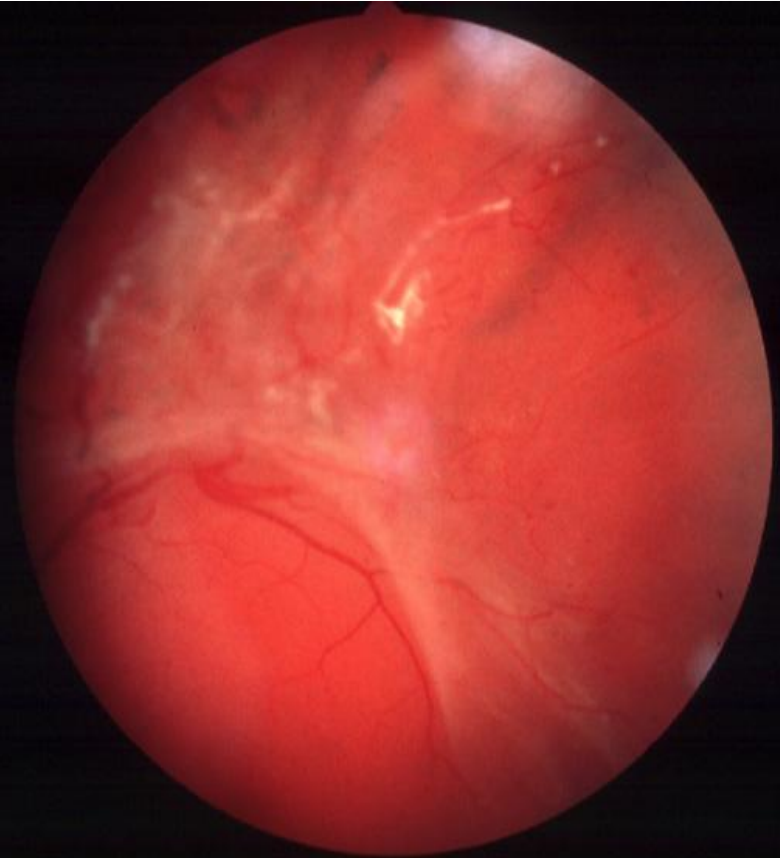
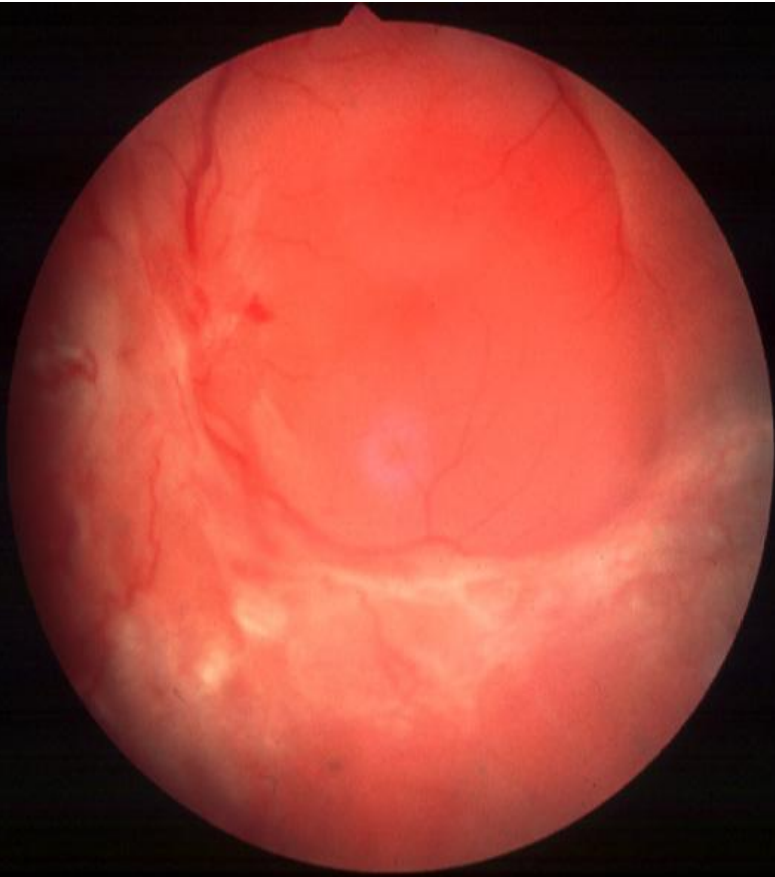

**Proliferații progresive**

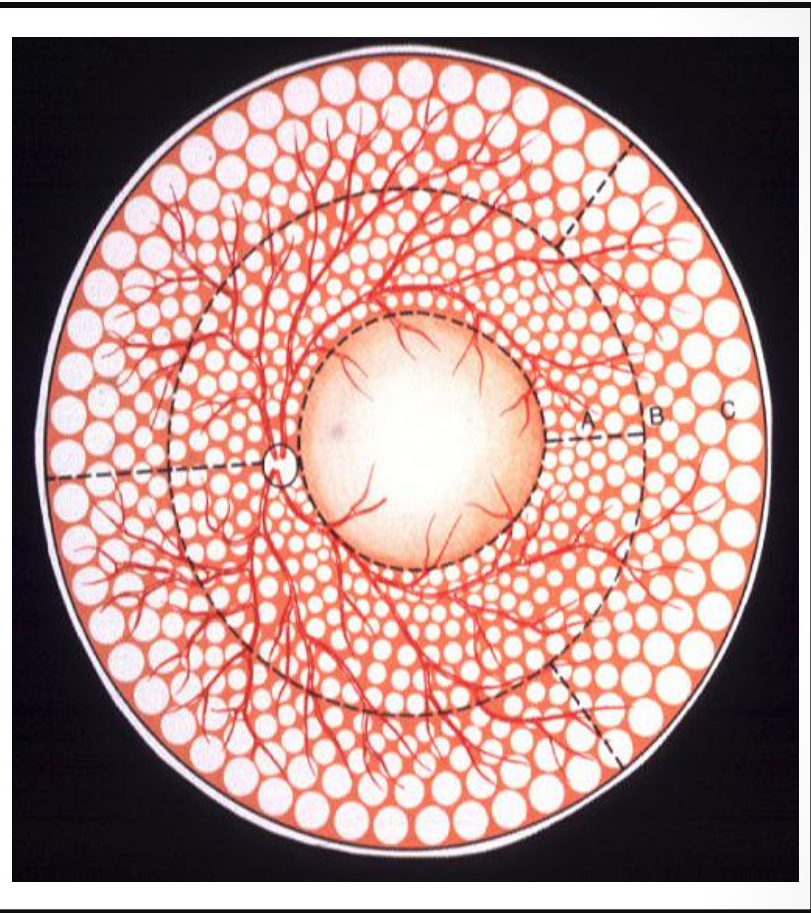
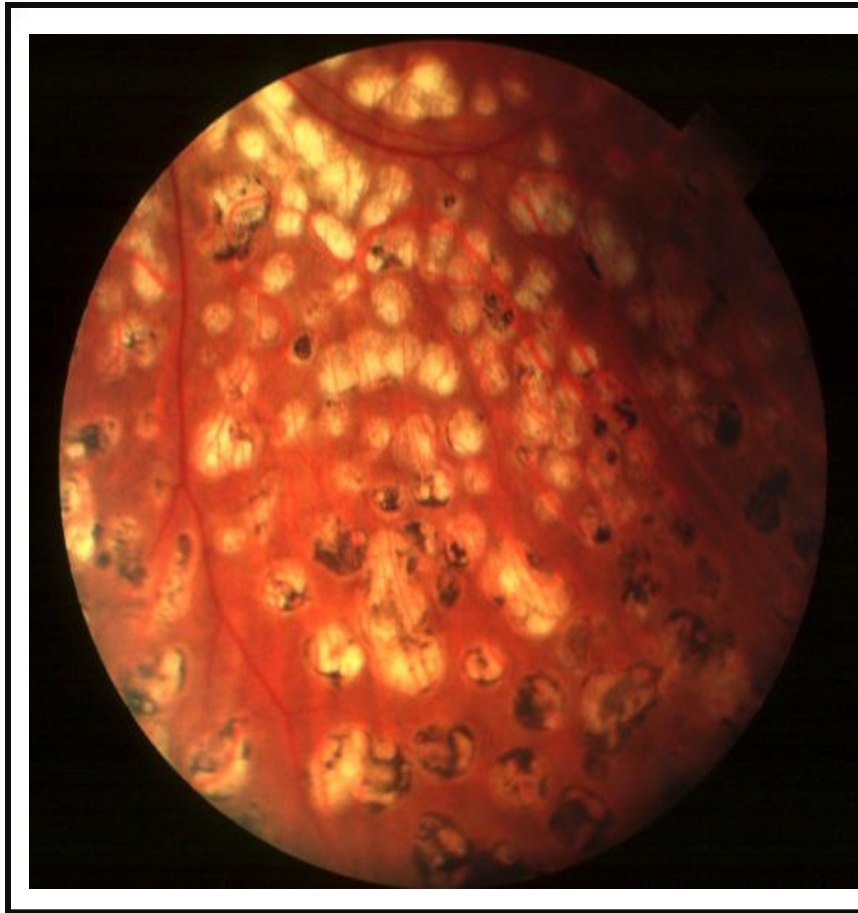


**Decolare de retină**

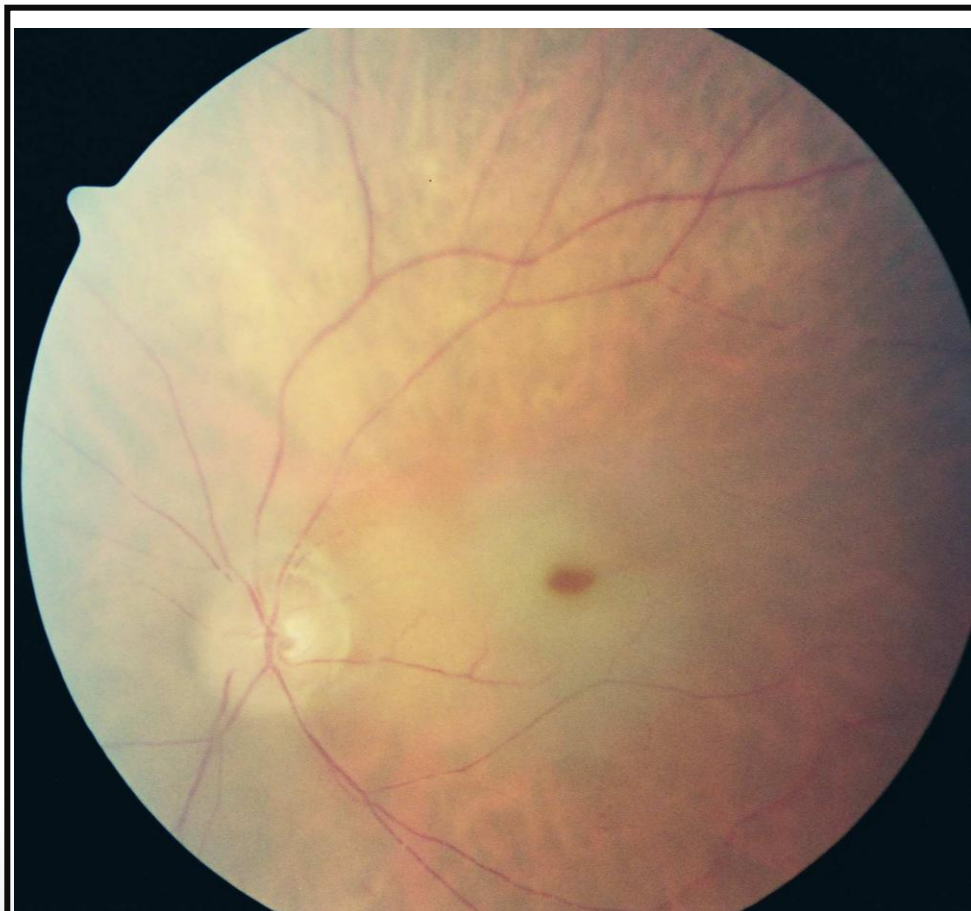
# Decolarea de retină tracțională



# Panfotocoagularea lazer a retinei

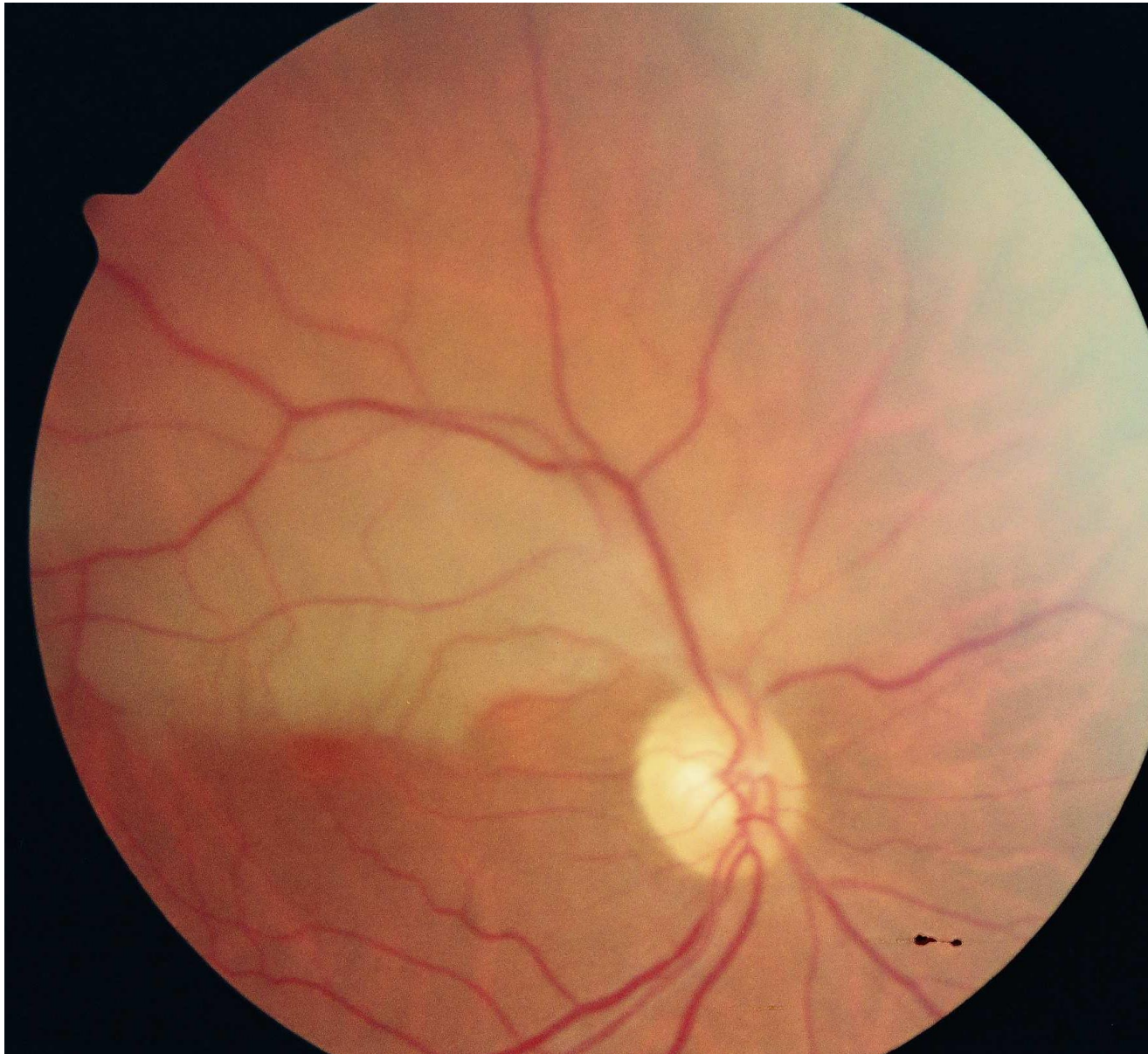


# Ocluzia arterei centrale a retinei

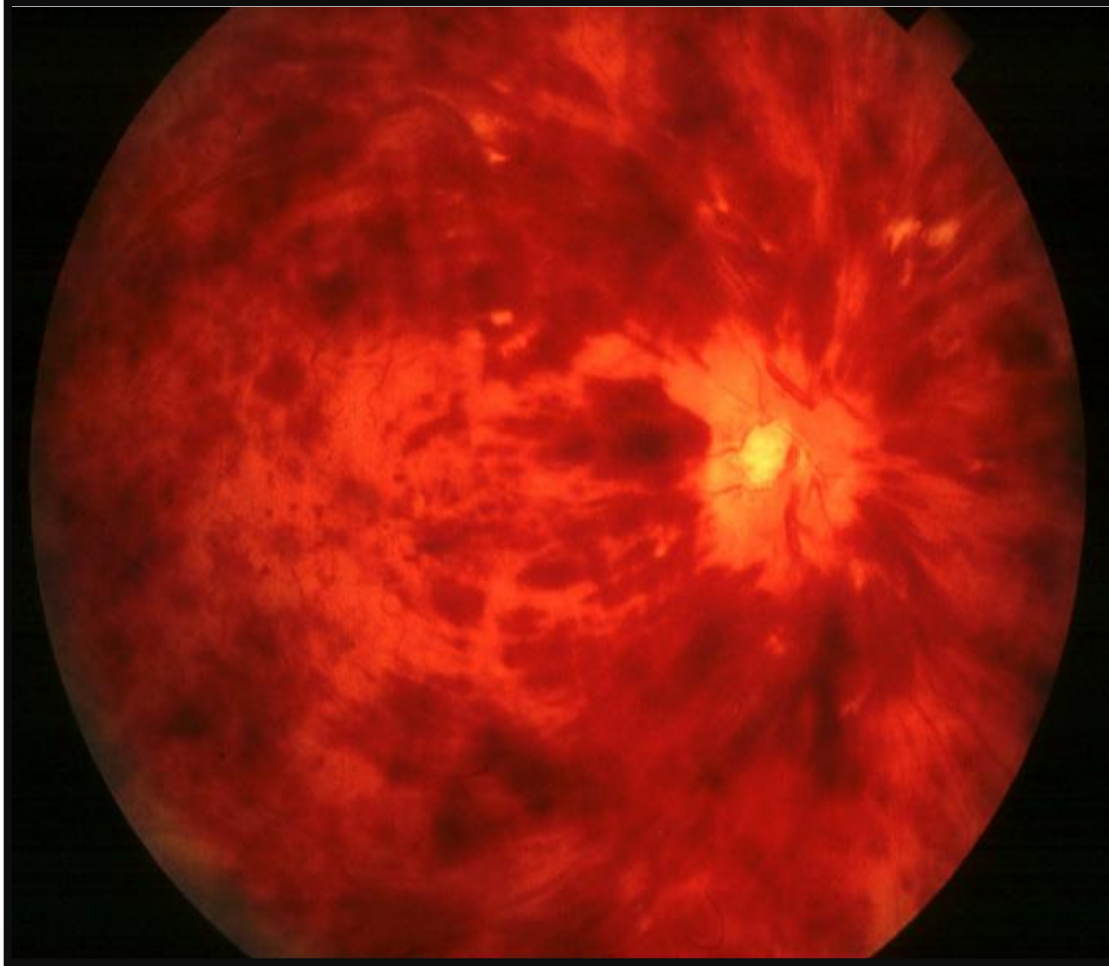

- **AV plc – “0”**
- **Retina alba, laptoasa**
- **‘Sambure de visina’ in macula**
- **Ingustarea arteriilor si venelor**
- **Segmentatia circulatiei sangvine**
- **Proгноza foarte nefavorabila**

# Ocluzia ram arterei centrale a retinei



# Tromboza venei centrale a retinei



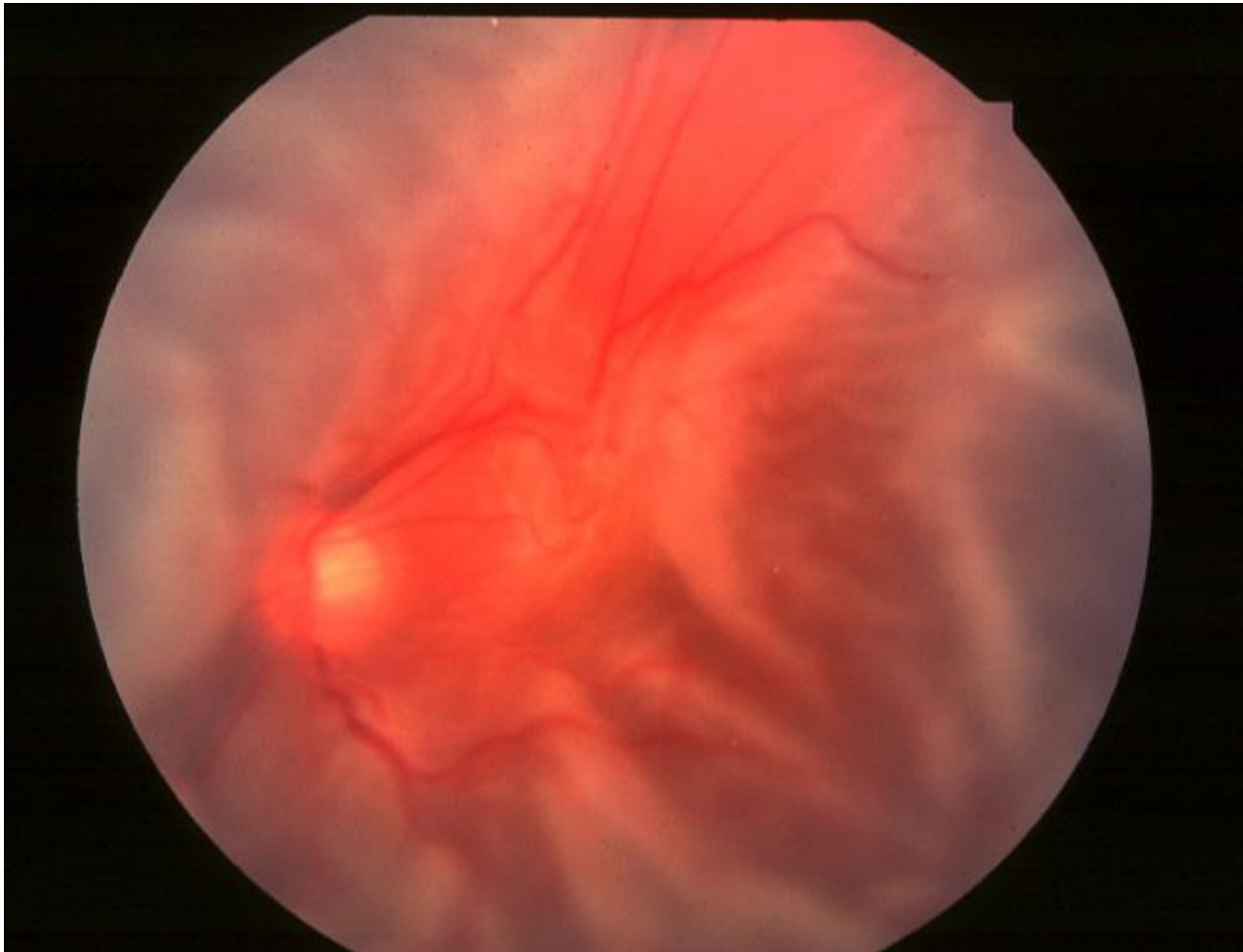
- **AV < 6/60**
- **Sinuositate venoasa**
- **Marcanta**
- **Hemoragii retiniene extinse**
- **“sm. Tomatei strivite”**
- **Exudate moi**
- **Edem al PNO sever**
- **Proгноza nefavorabila**
- **Rubeosis irides in 50%**



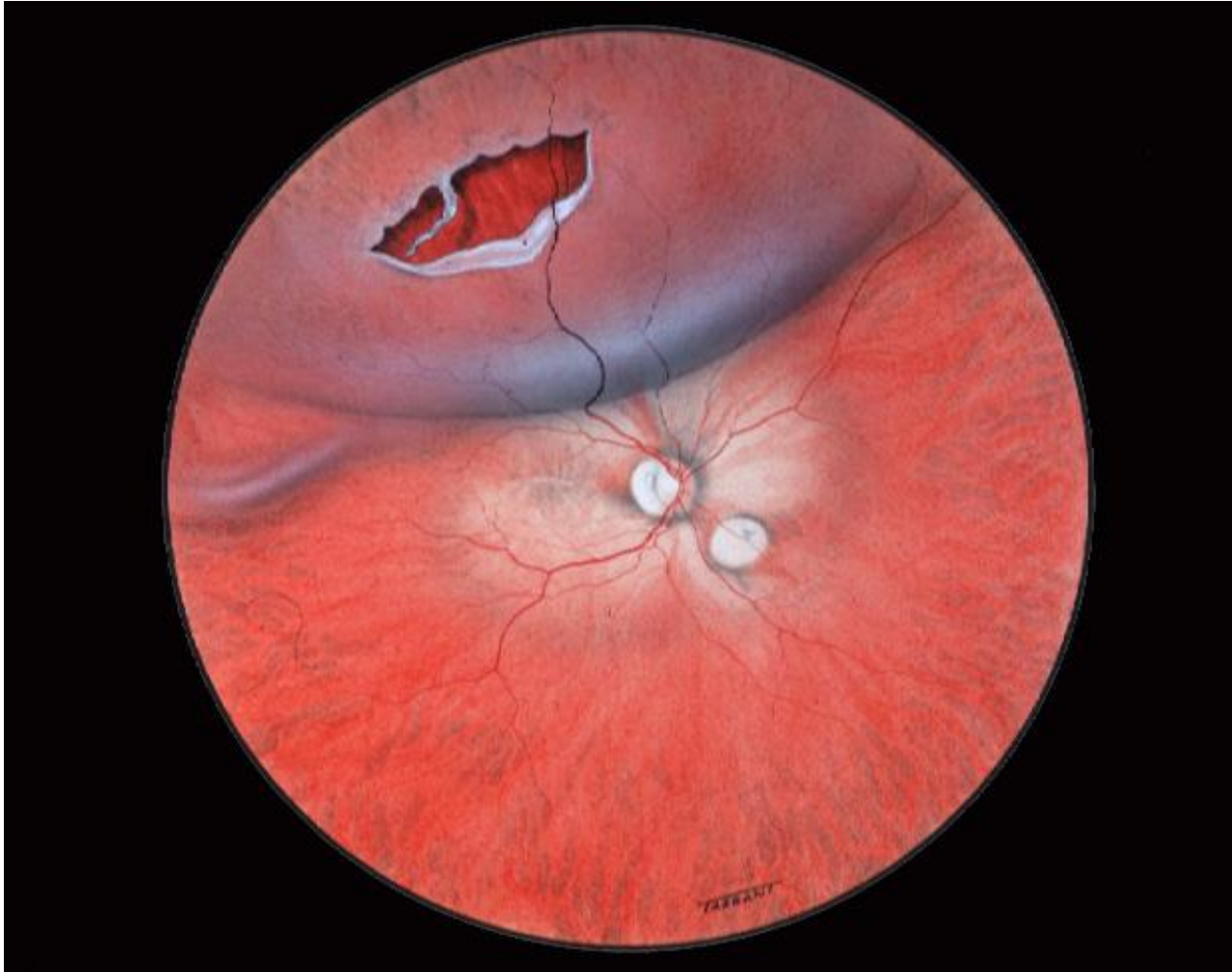
# Decolarea de retină

- **Primară** – regmatogenă
- **Secundară:**
  - exudativă
  - tracțională

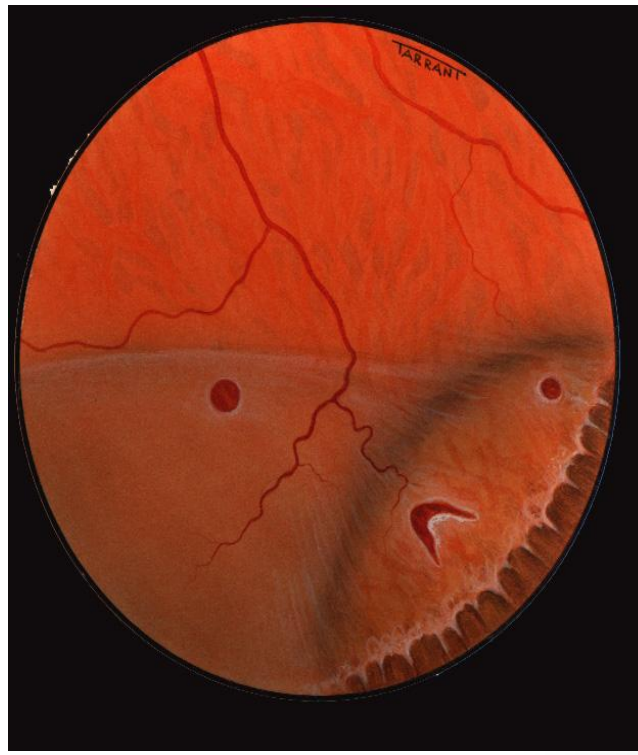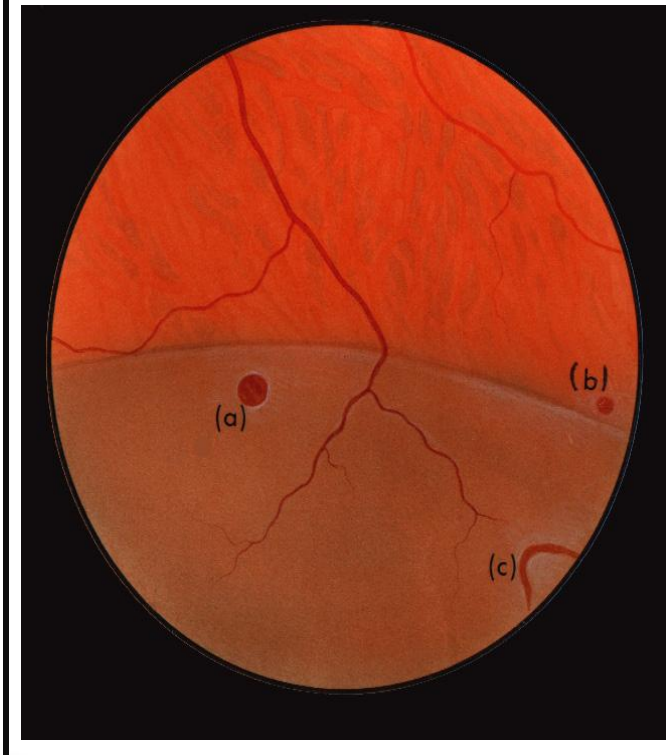
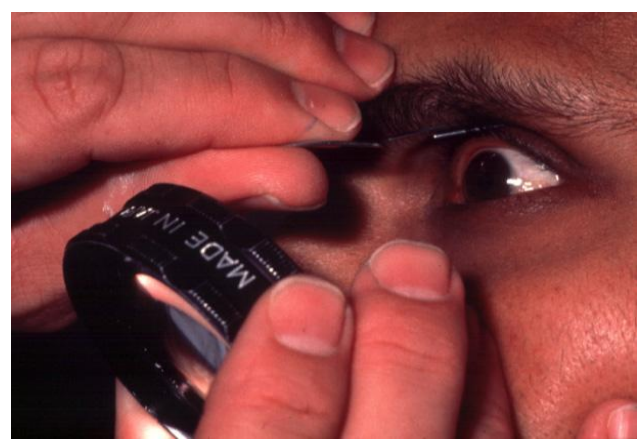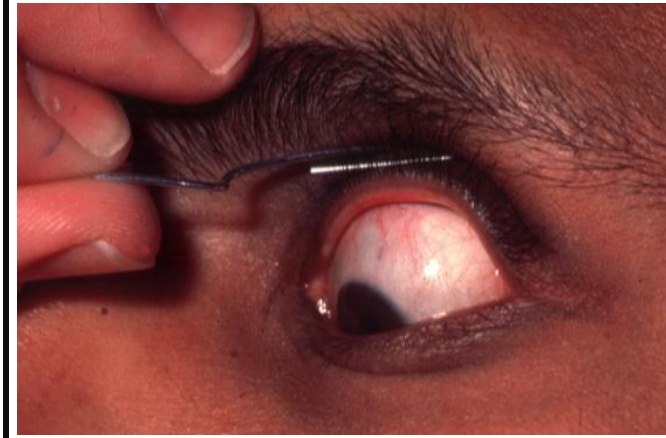# Decolarea de retină regmatogenă



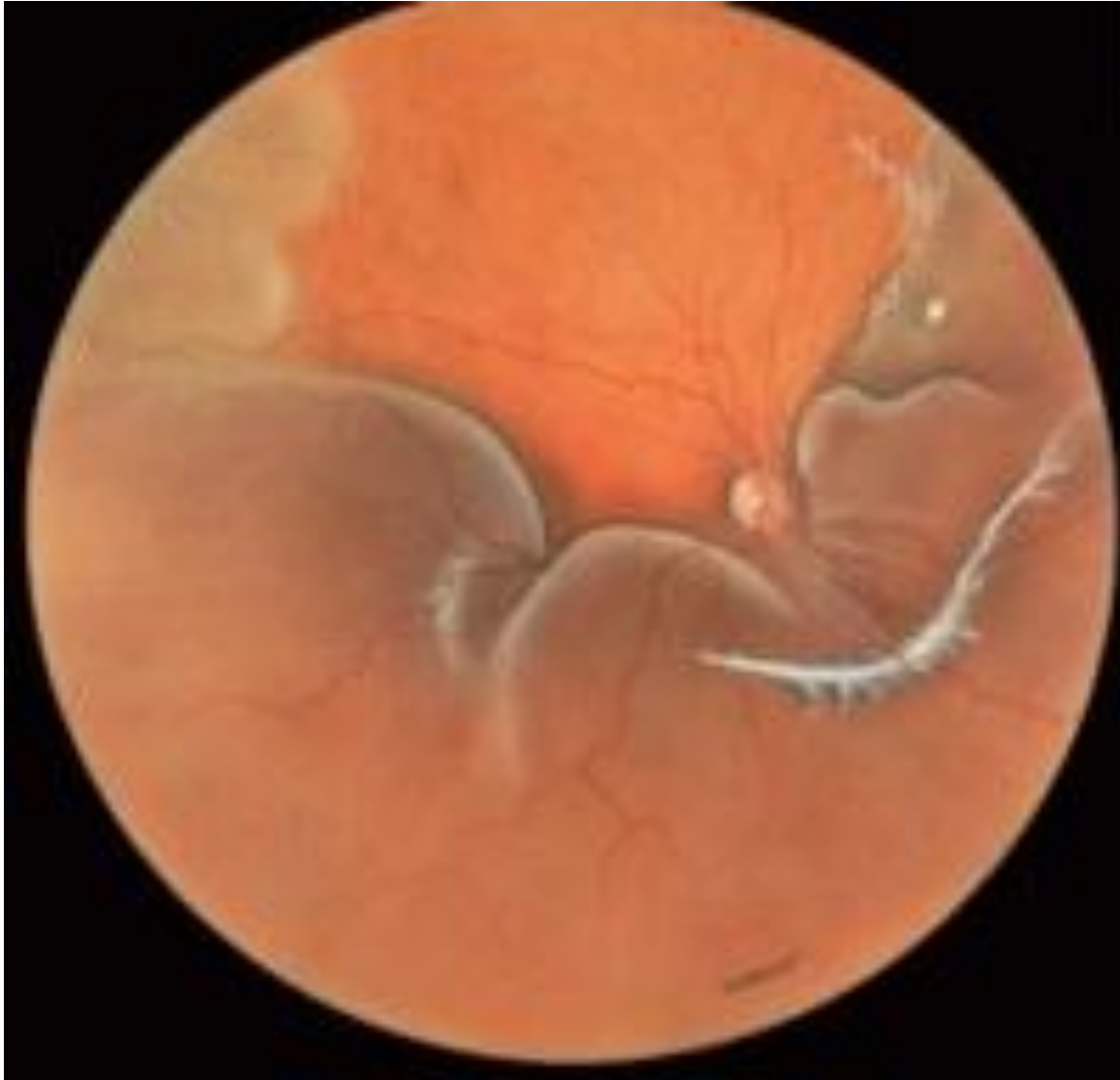# Decolarea de retină regmatogenă



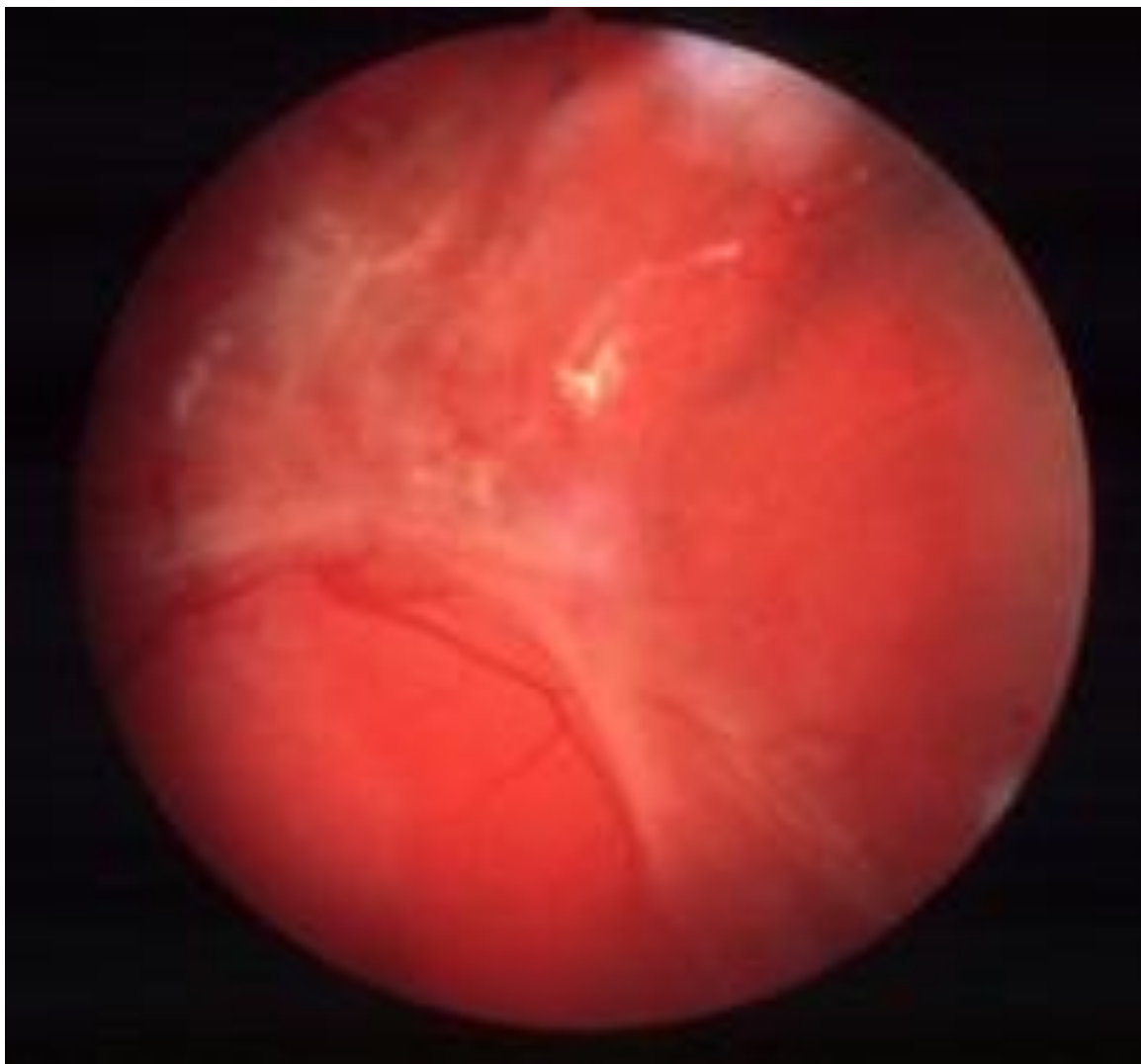
# Metoda de examinare



# Decolarea de retină exudativă

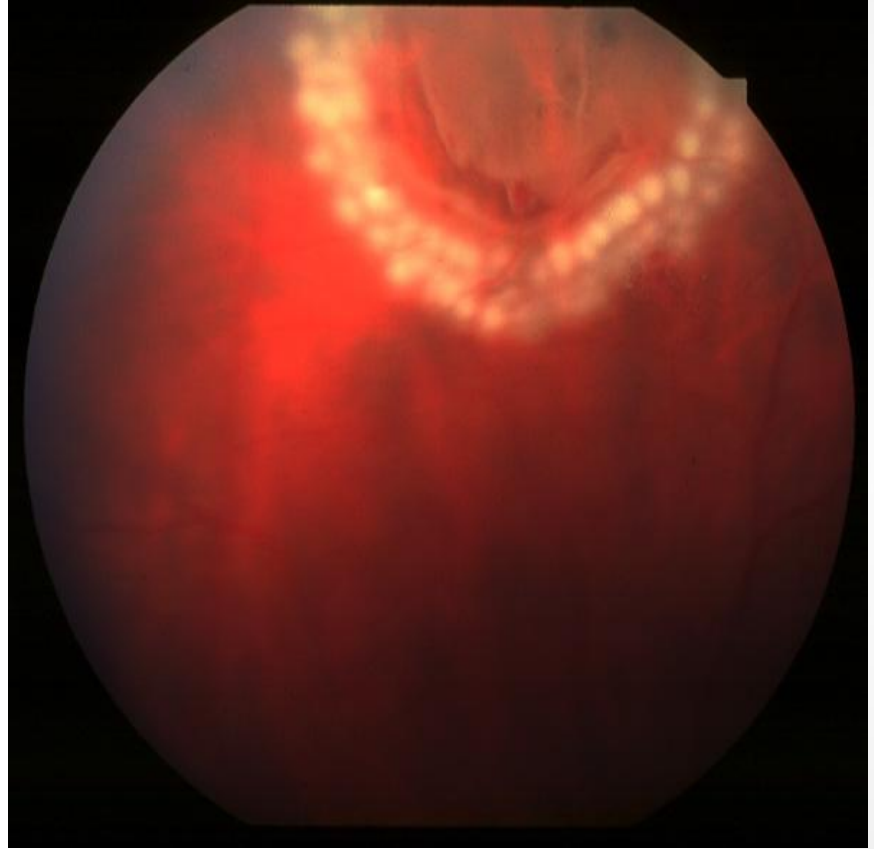
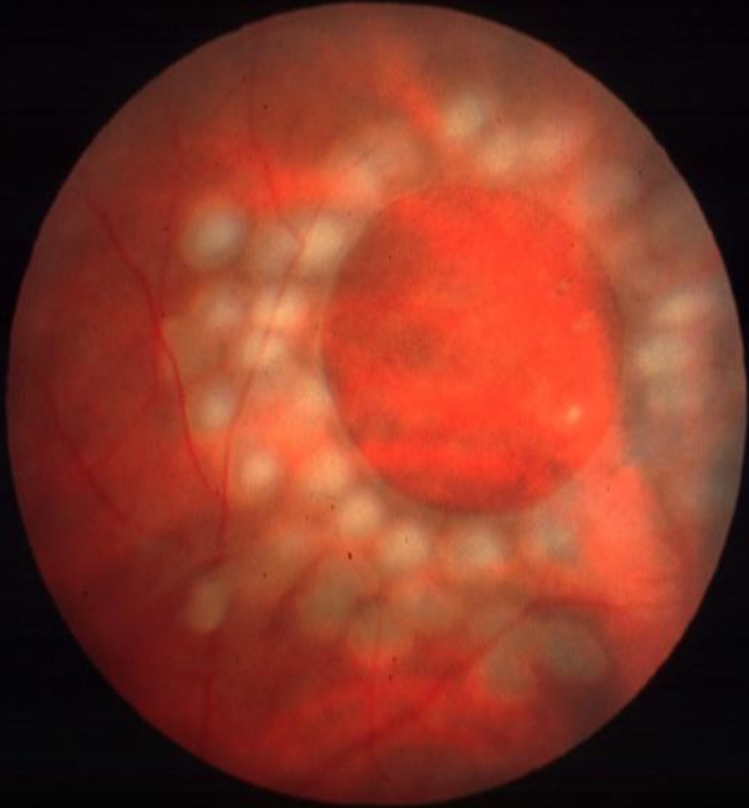


# Decolarea de retină traccională

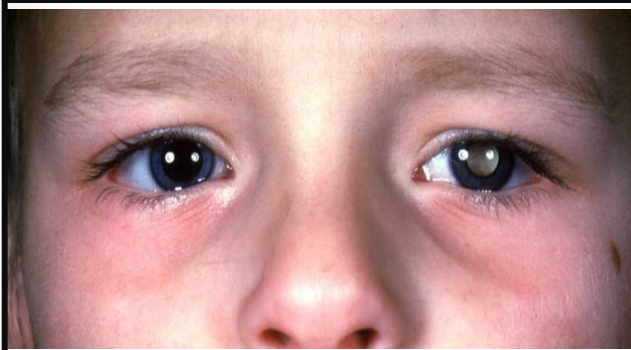

# Profilaxia decolării de retină regmatogenă

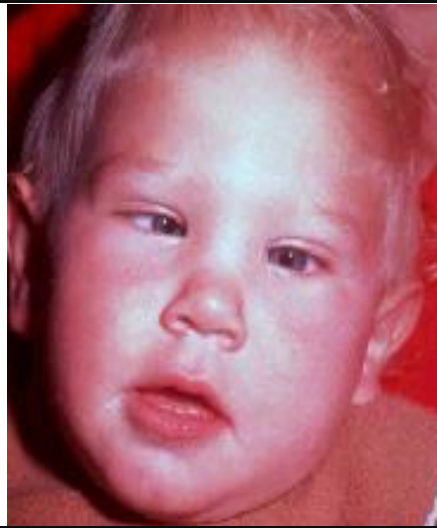## Coagularea lazer a retinei



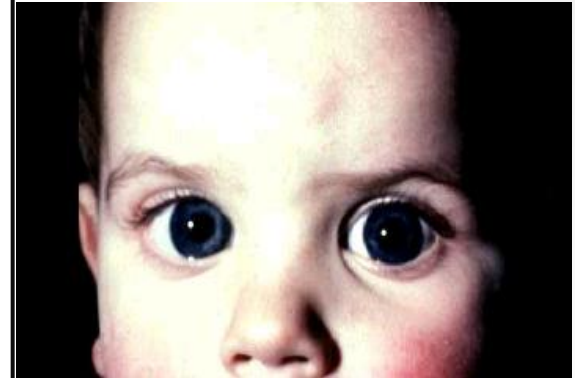# Retinoblastomul



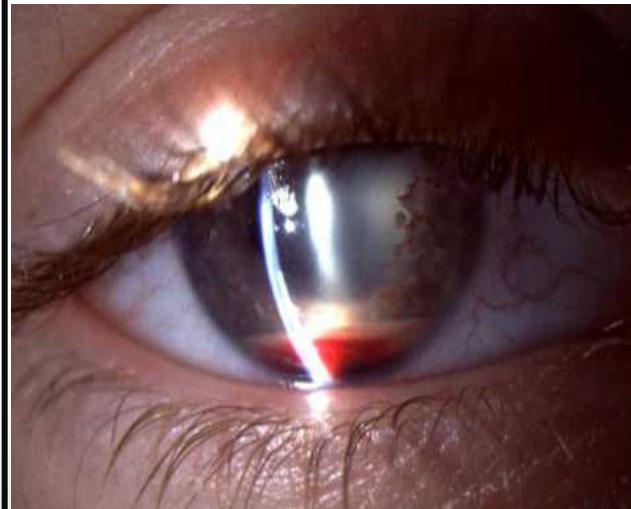**•Leucocoria - 60%**



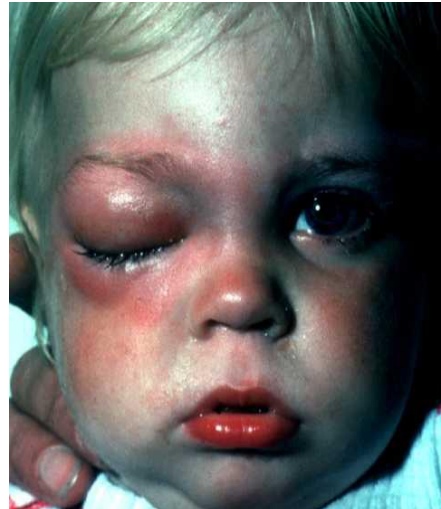**Strabizm- 20%**



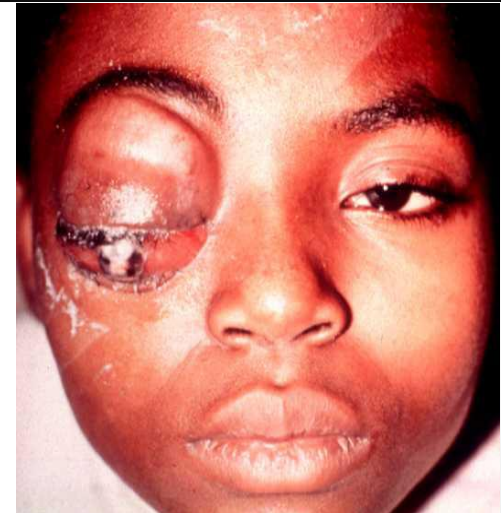**Glaucom secundar**



**• Invadarea segmentului anterior**



**Inflamatii orbitale**



**Invazie orbitală**