

UVEITIS

DM DR. ANGELA CORDUNEANU

Classification

Anterior uveitis:

- Iritis
- **Cyclitis**
- **Iridocyclitis**

Peripheral uveitis

- **parsplanitis**
- **peripheral uveitis**

Posterior uveitis:

- **choroiditis**
- **chorioretinitis**
- **retinochoroiditis**

Generalized uveitis

- **panuveitis**

Classification Evolution

- Acute
- Chronic
 - **Latent**
 - **Relapsed**

Classification

Morphopathology of the inflammatory process

- **Granulomatous inflammatory process**
- **Nongranulomatous inflammatory process**

THE WAY OF THE PENETRATION OF THE INFECTION

- **Exogenous**
- **Endogenous**

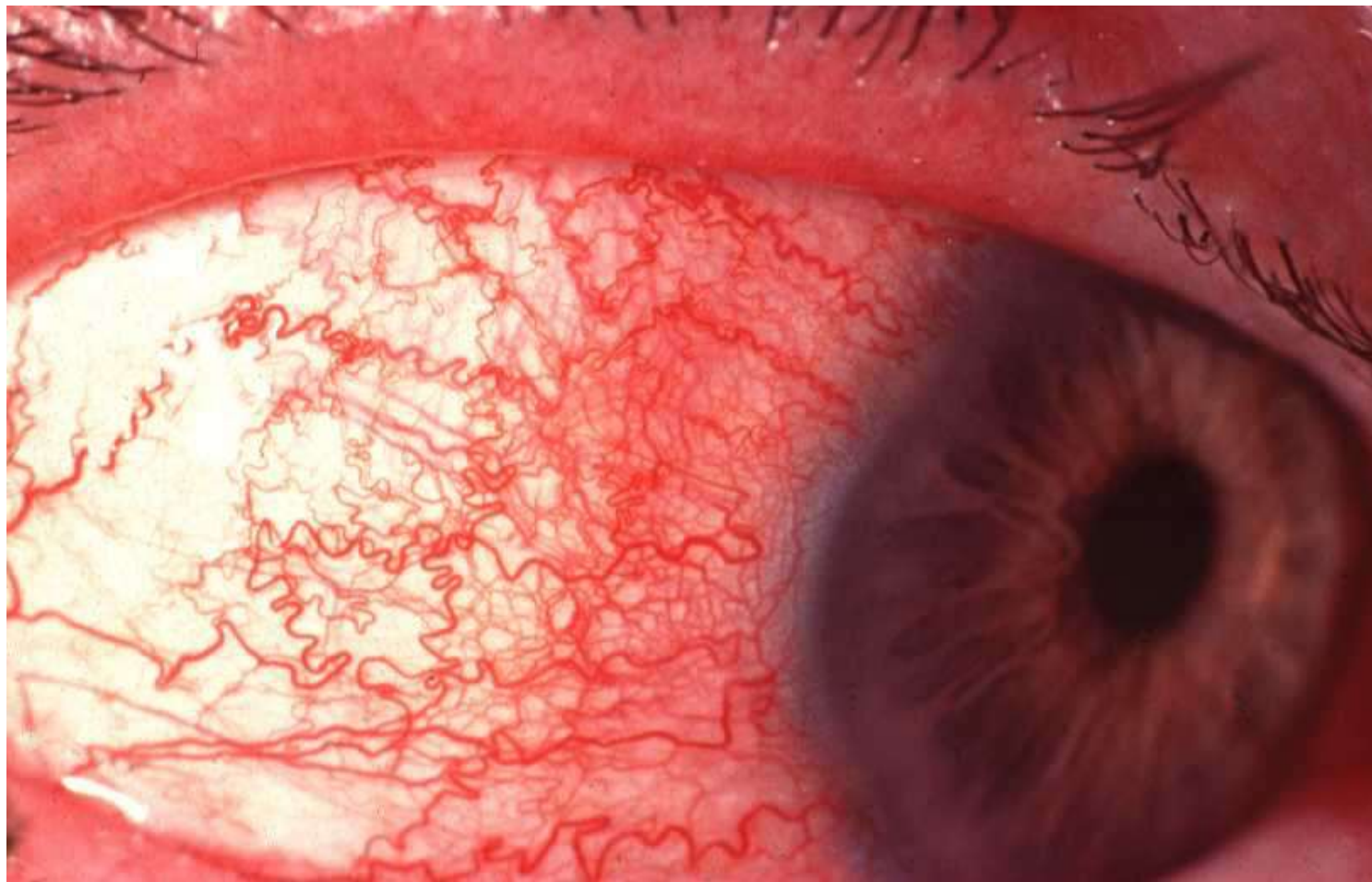
ETIOLOGY

- **Viral: CMV, Herpes virus, Epstein Barr virus ...**
- **Bacterial infection**
- **Fungus: candidiasis, histoplasmosis**
- **Parasitic: toxocariasis, toxoplasmosis**
- **Rickettsia: chlamidiosis**
- **Mycobacteria: tuberculosis, leptospirosis**
- **Spirochete: Lues, Lyme Borelioza**
- **Sarcoidosis**
- **Systemic deseases: reumatism, Behcet deseases, Best, Reiter, Juvenil arthritis, Erythematosus lupus**
- **Idiopathic**

CLINIC OF THE *IRIDOCYCLITIS*

- Ocular and periocular pain, *increase at the palpation of the eyeball and at night*
- Photophobia
- Lacrimation
- Decrease of the visual acuity
- Eyelid edema
- Eyeball hyperemia (pericorneal)

PERICORNEAL REDNESS



Clinical of the *Iridocyclitis*

- **Corneal edema**
- **Decrease of the size of anterior chamber**

ANTERIOAR UVEITIS NONGRANULOMATOUS

- **Precipitated on the corneal endothelium**
- **Corneal edema**
- **decrease of the size of anterior chamber**

IRIDOCYCLITIS GRANULOMATOUS

- **Precipitated on the corneal endothelium**

EXUDATIVE REACTION IN

- **Serous**
- **Purulent - hypopyon**
- **Hemorrhagic - hyphaema**
- **Fibroplastic**

INTRAOCULAR PRESSURE

- **Hypoton <15**
- **Hyperton >26**
- **Normotonic**

COMPLICATION OF THE IRIDOCYCLITIS

■ **Keratopathy**

■ **Posterior synechiae**

■ **Cataract**

Seclusion of the pupil

Oclusion of the pupil

ADDITIONAL EXAMINATION

- **Gen.blood analysis, urine**
- **Immunological tests: Ac, Ig, RW ...**
- **Rheumatic samples**
- **Rgr orbits, paranasal sinuses, lungs**
- **Consultation of the : therapist, rheumatologist, ENT, stomatologist, , dermatovenerologist...**

TREATMENT OF THE IRIDOCYCLITIS

- First aid:** administration of the mydriatic drops
(atropine, tropicamide, mezaton, phenylephrin..)
- **Etiological:** antiviral, antibacterial, antifungal ...
 - **Pathogenetic:** steroidal and nonsteroidal anti-inflammatory drugs, citostatic, immunosuppressive, immunomodulators drugs
 - **Symptomatic:** mydriatic, B-blockers, yeast , anticoagulants, diuretics, lasertherapy, physiotherapy...

CLINIC OF THE *POSTERIOR UVEITIS*

- **Photopsias**
- **Metamorphopsia**
- **Macropsii, micropsii**
- **Scotoma**
- **Decrease of the visual acuity**

COMPLICATION OF THE POSTERIOR UVEITIS

- **Chorioretinal atrophy**
- **neuroretinitis**
- **Exudative and tractional retinal detachment**
- **Opacification of the vitreous**
- **Cataract**
- **Generalization of the inflammatory process**

TREATMENT

- **Etiological**
- **Pathogenetic**
- **Symptomatic**